



Surgical Progression of a Maxillofacial Trauma Patient Sustaining an Industrial Accident

Joshua Blanton-Dickens
PGY 4



Disclosure

Surgical Progression of a Maxillofacial Trauma Patient Sustaining an Industrial Accident

Joshua Blanton-Dickens, DMD

The following potential conflict of interest relationships are germane to my presentation.

Equipment: None
Speakers Bureau: None
Stock Shareholder: None
Grant/Research Support: None
Consultant: None

Status of FDA devices used for the material being presented
NA/Non-Clinical

Status of off-label use of devices, drugs or other materials that constitute the subject of this presentation
NA/Non-Clinical



Objectives

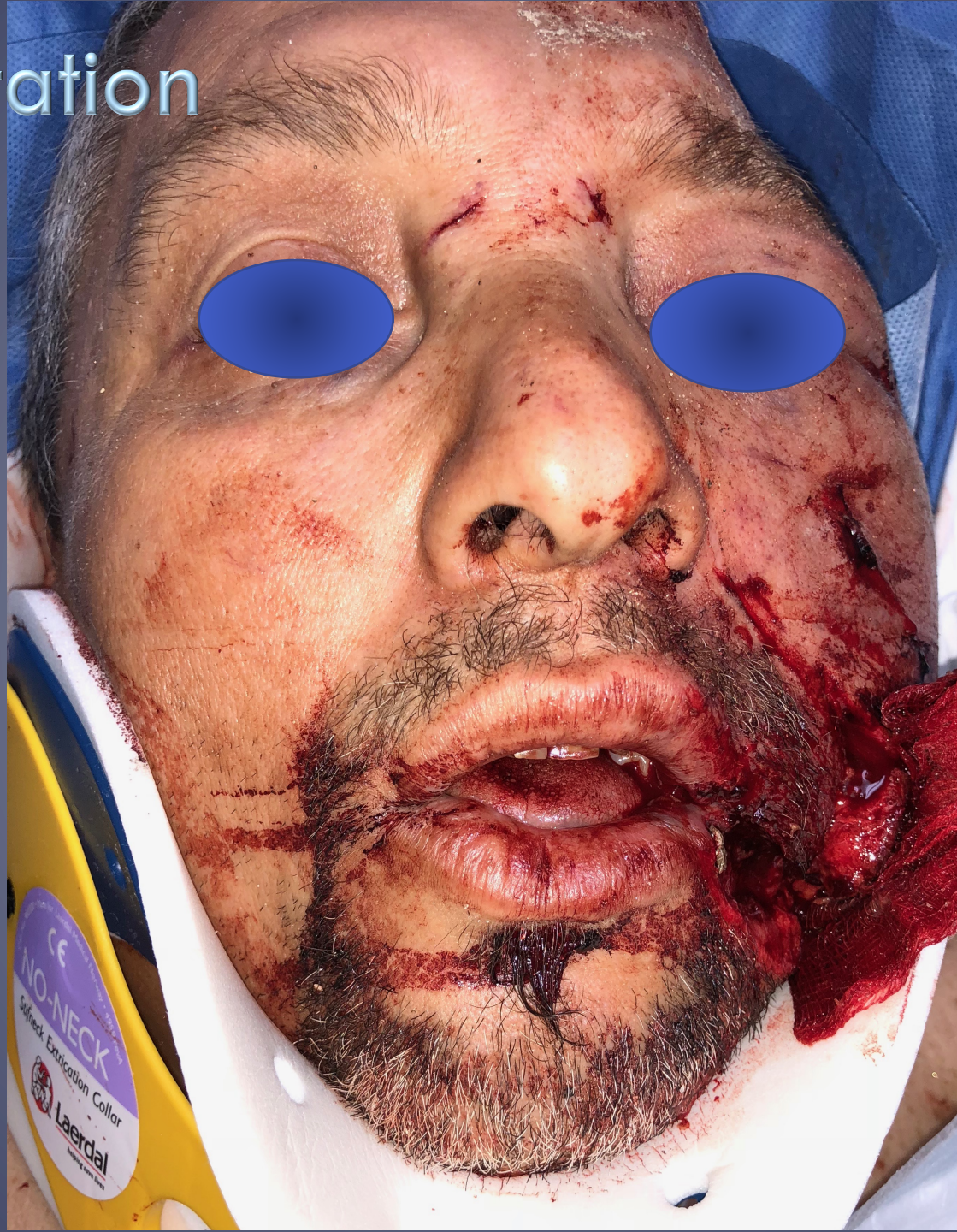› Phase I

- Initial Trauma
- Work-Up
 - › Fracture Identification
- Planning
 - › Surgical Sequencing
 - › Surgical Approaches
- Treatment
- Evaluation of Fracture Reduction

› Phase II

- Dentoalveolar Reconstruction
 - › Bone Grafting
 - › Dental Implants

Patient Presentation



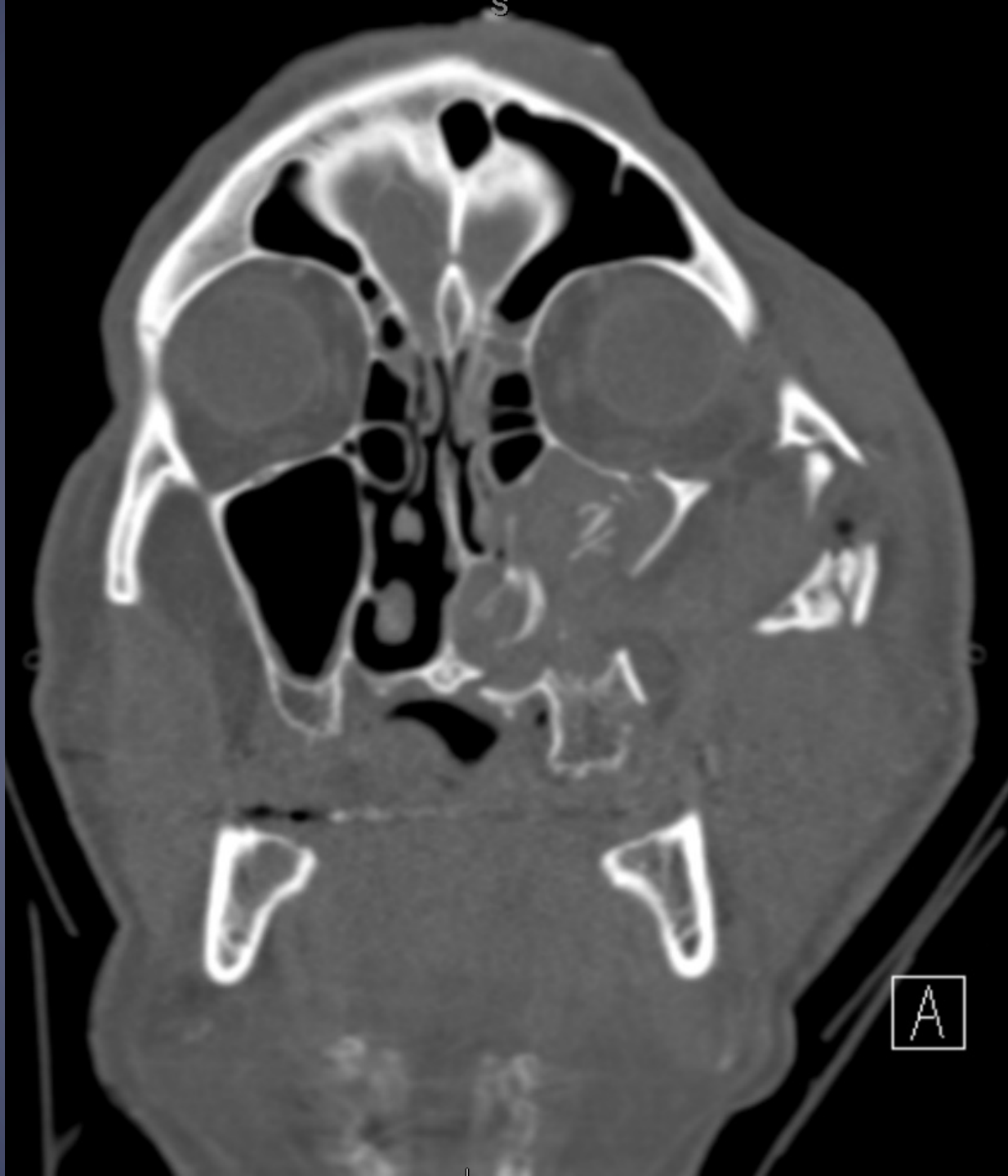


PHASE I

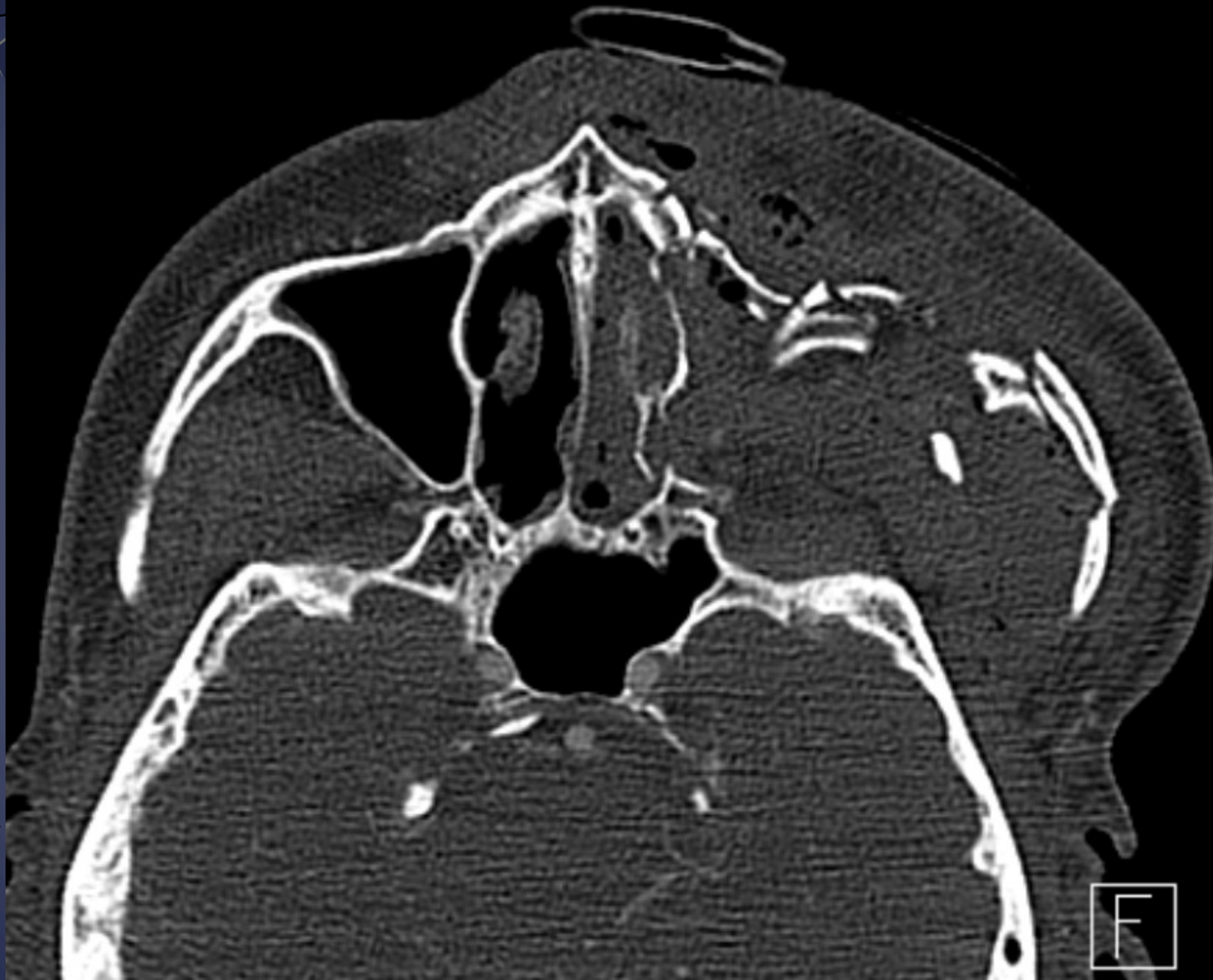

FRACTURE EVALUATION


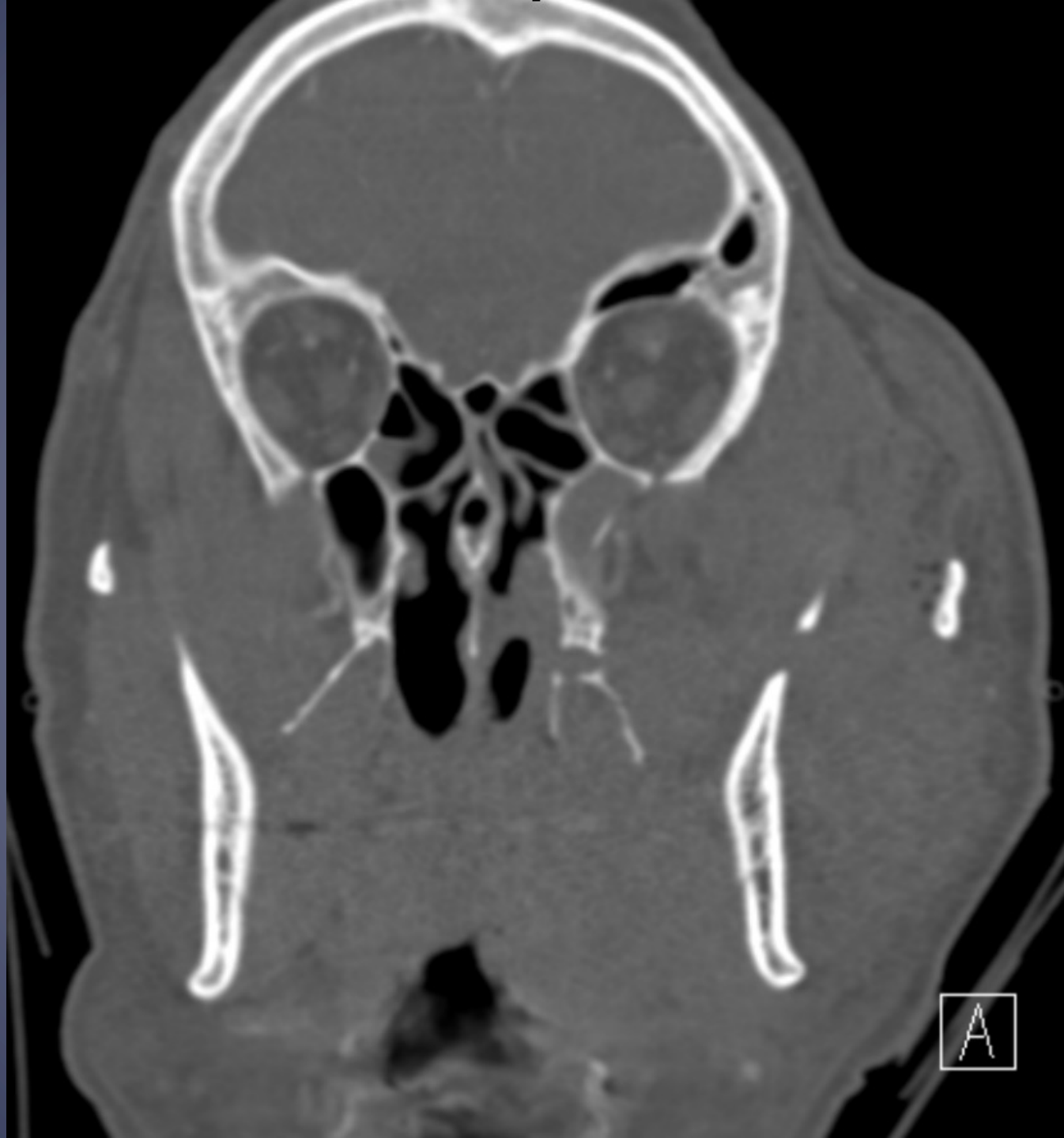

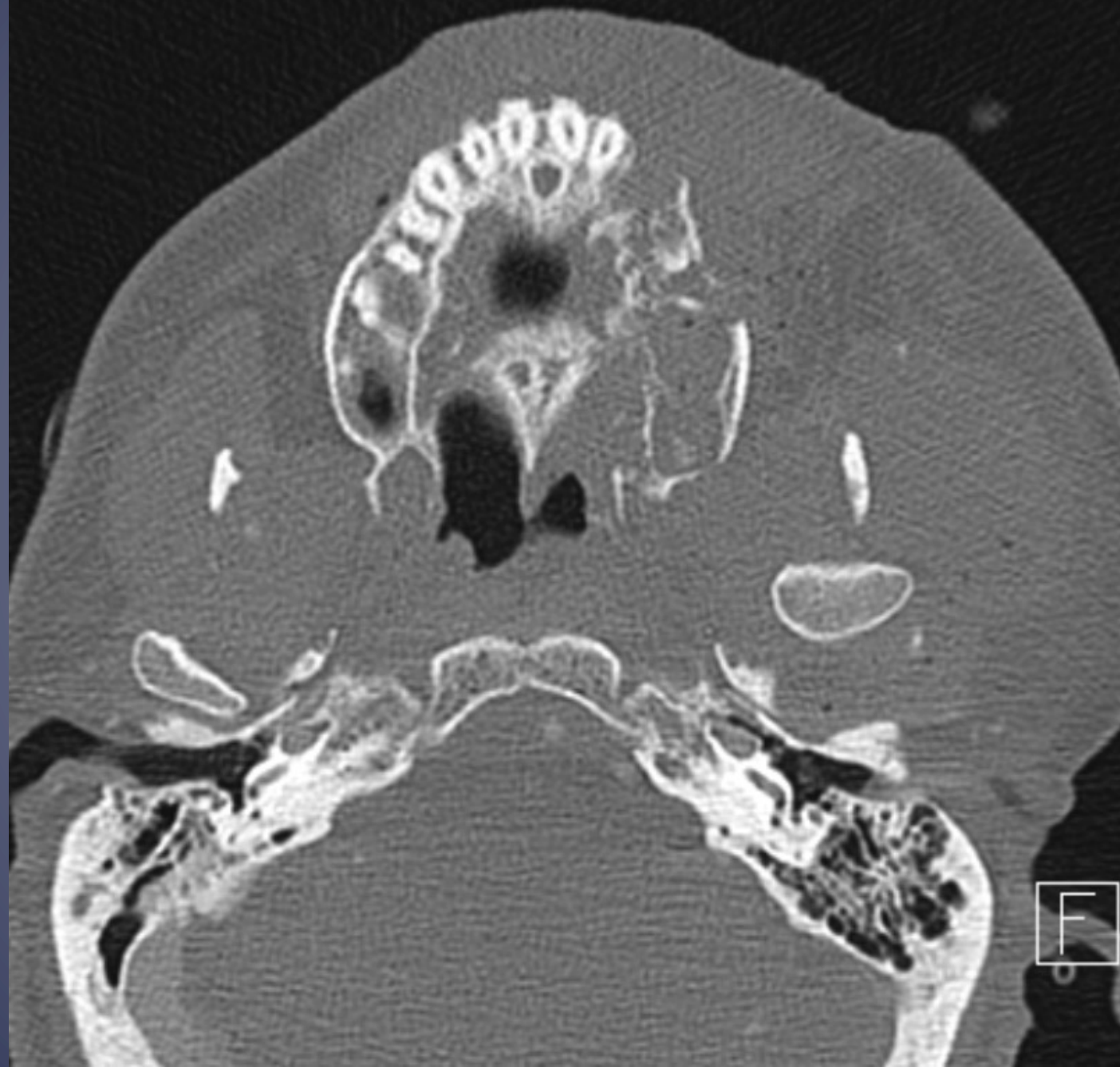



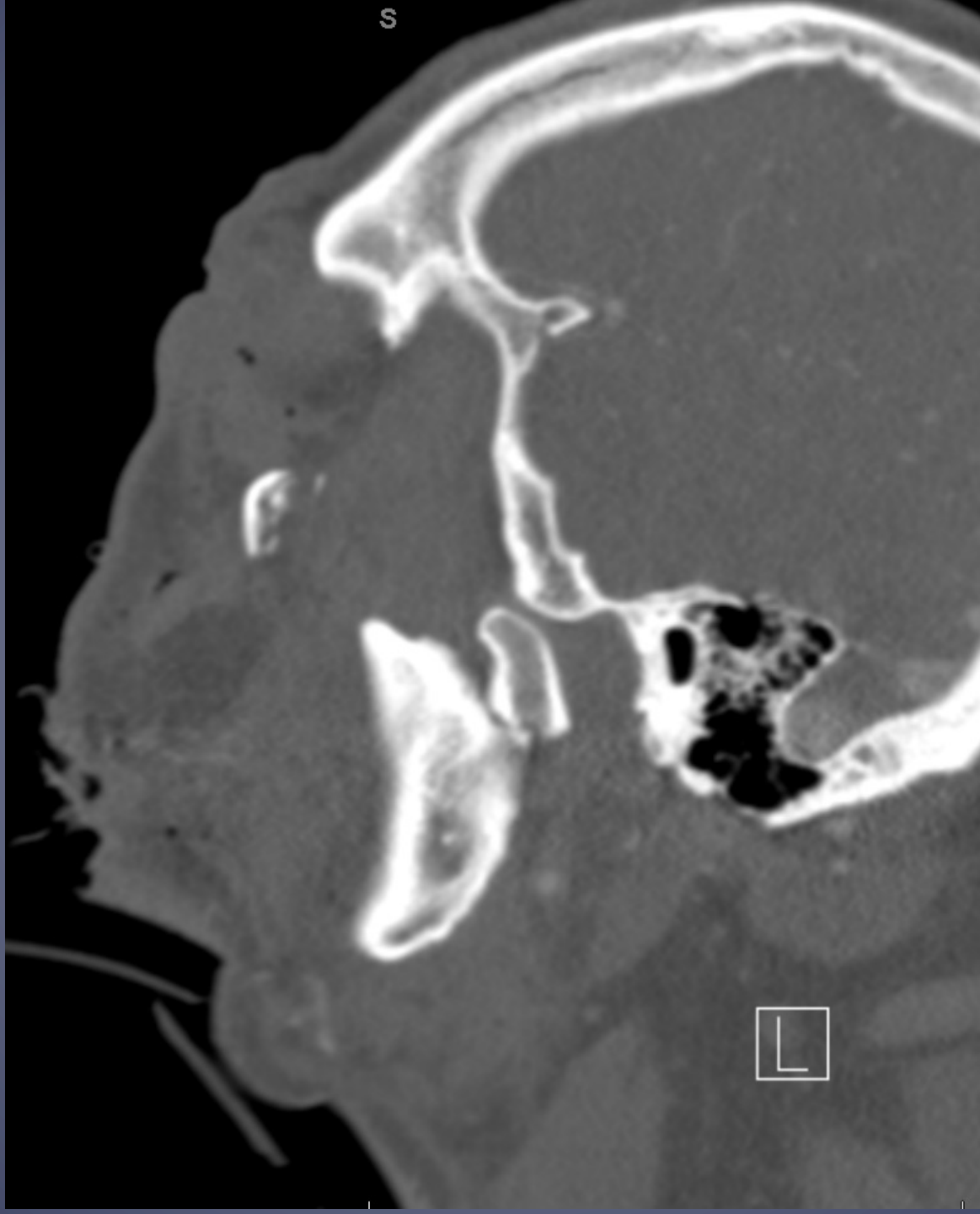

A

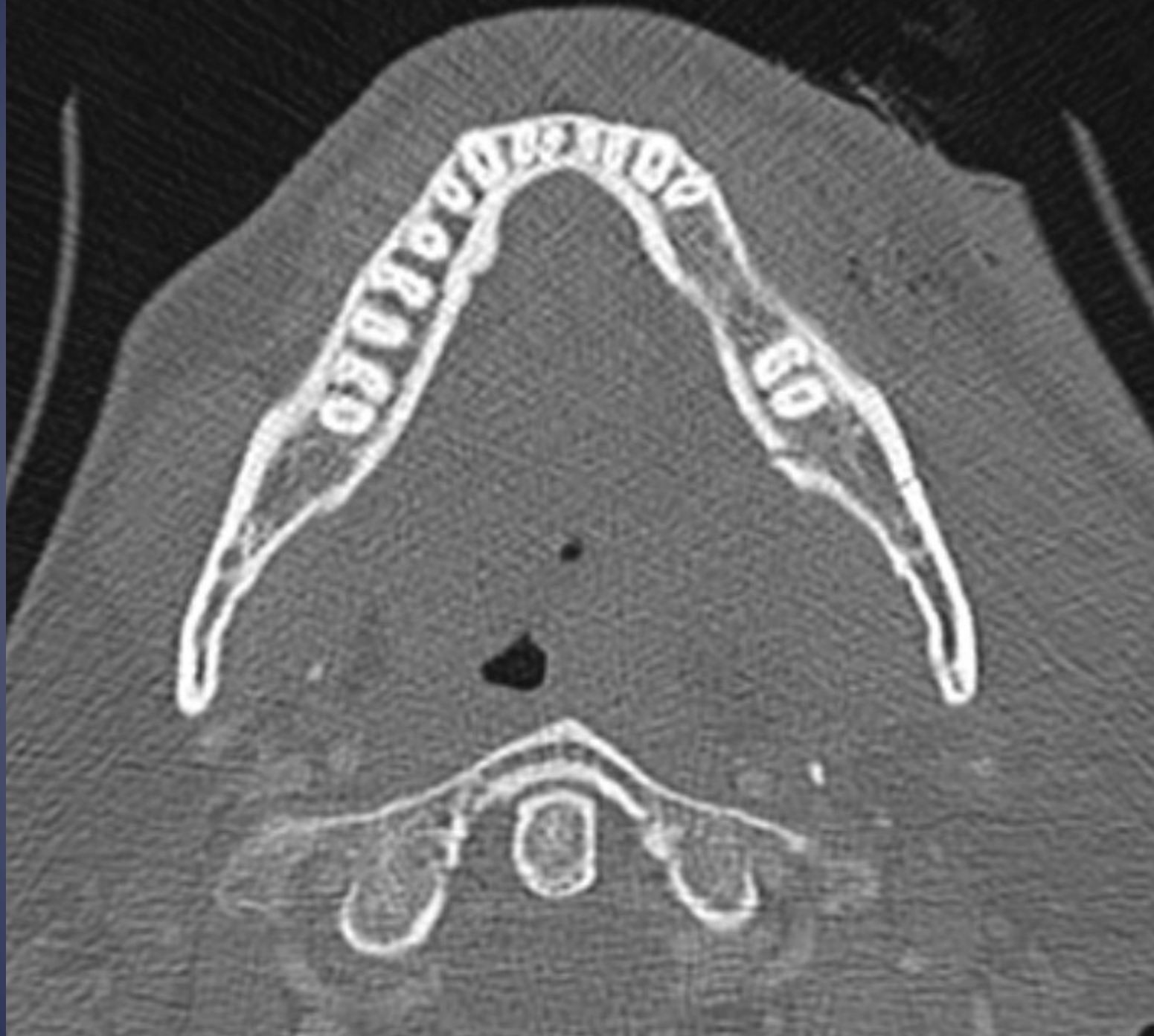



F

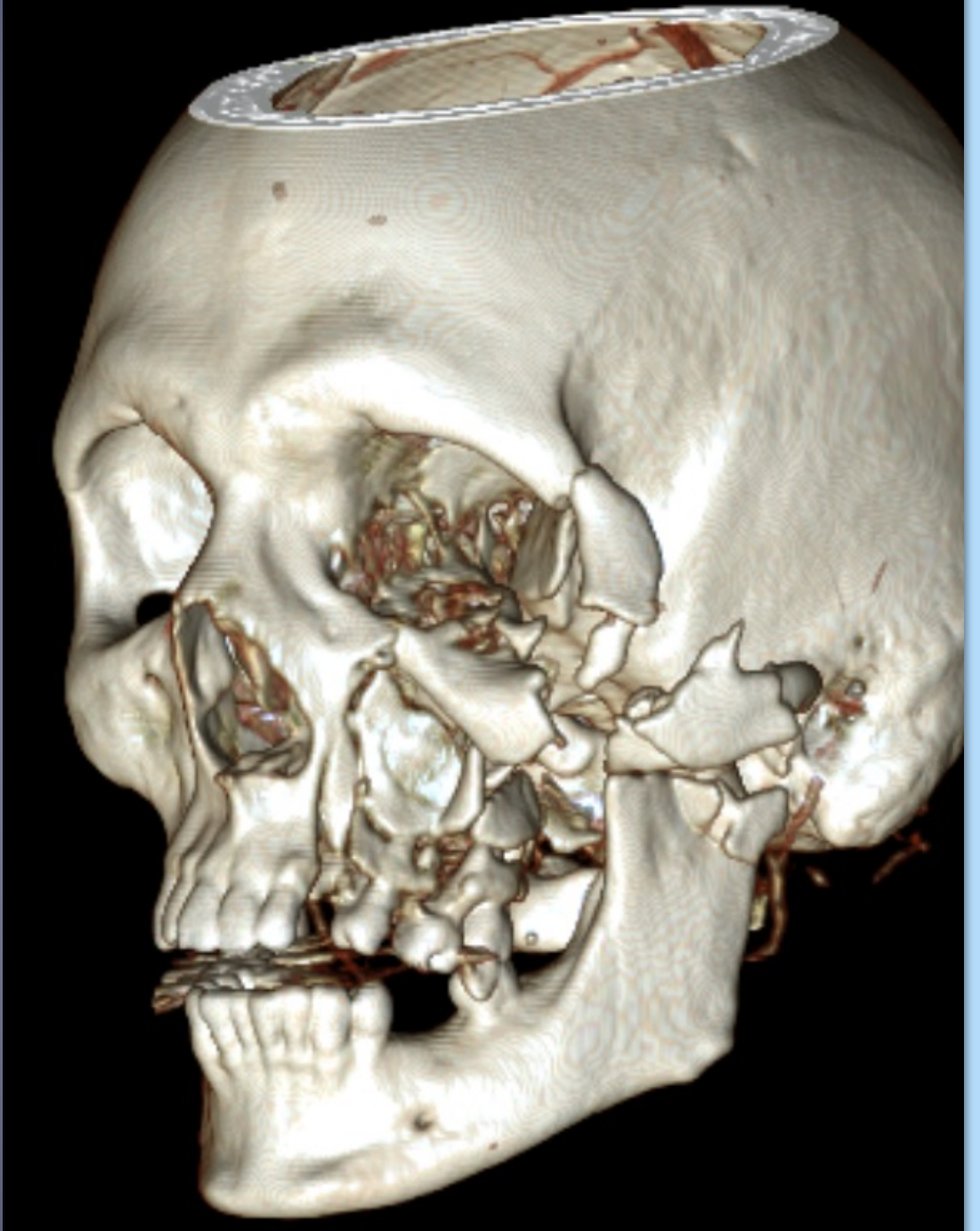
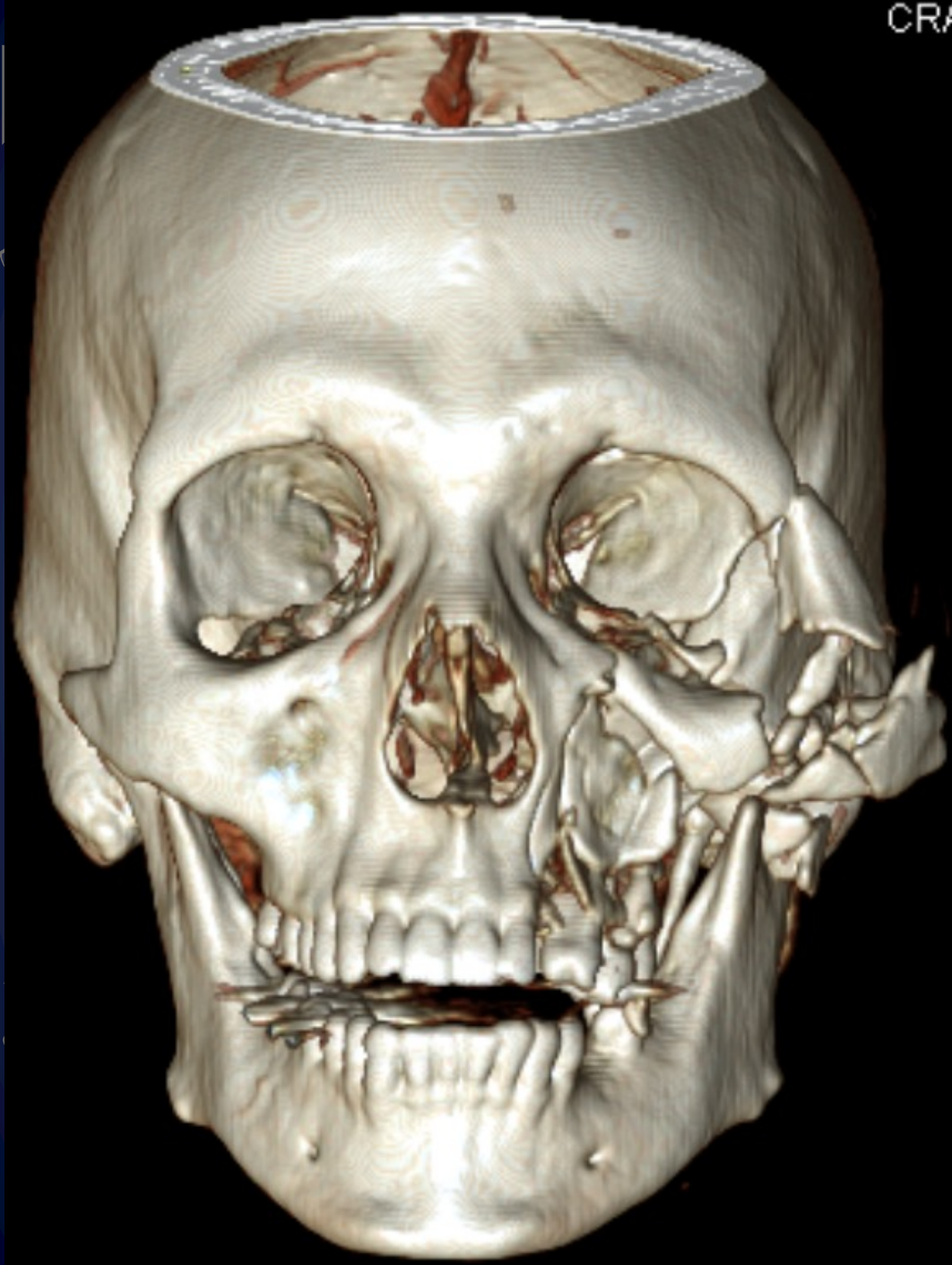


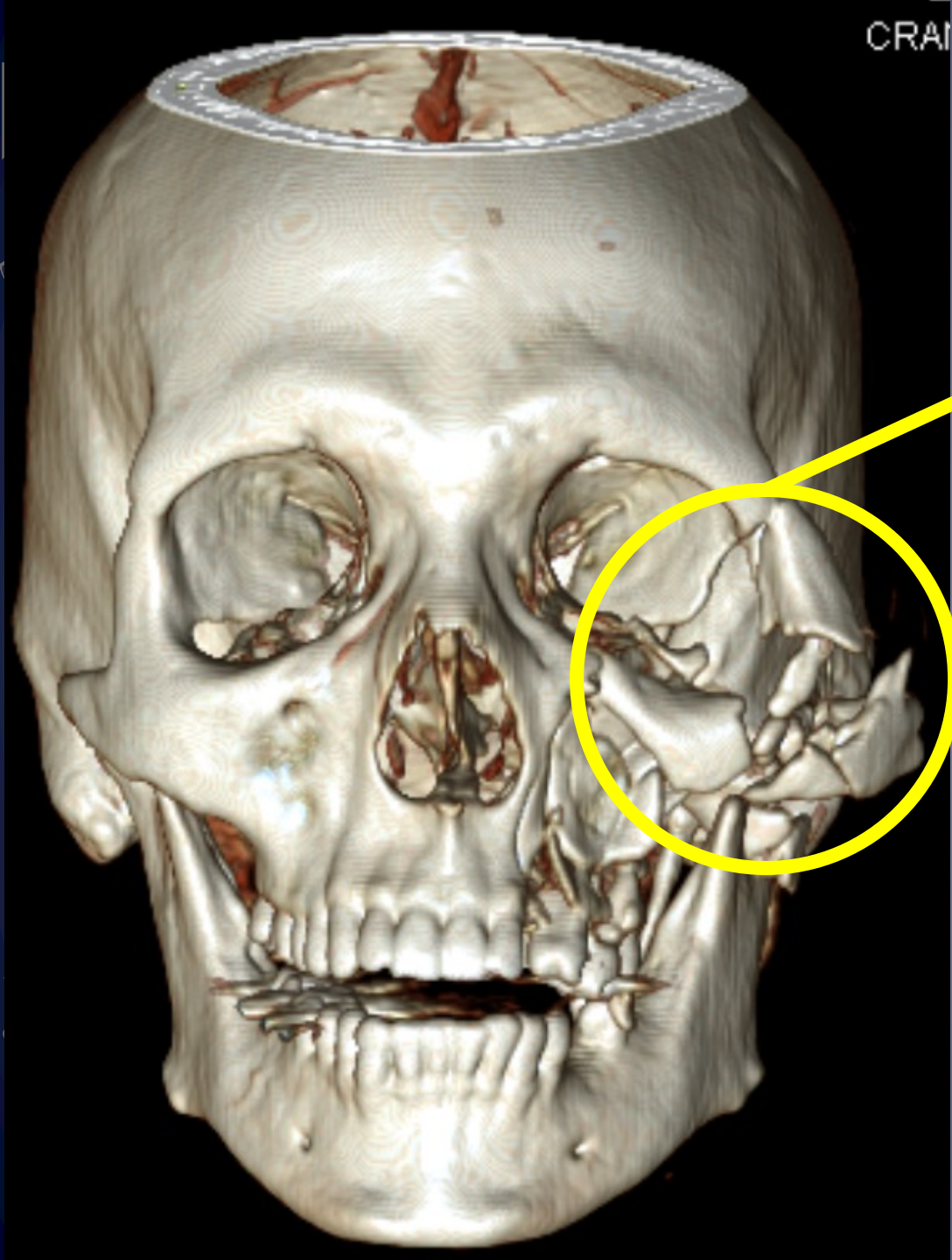




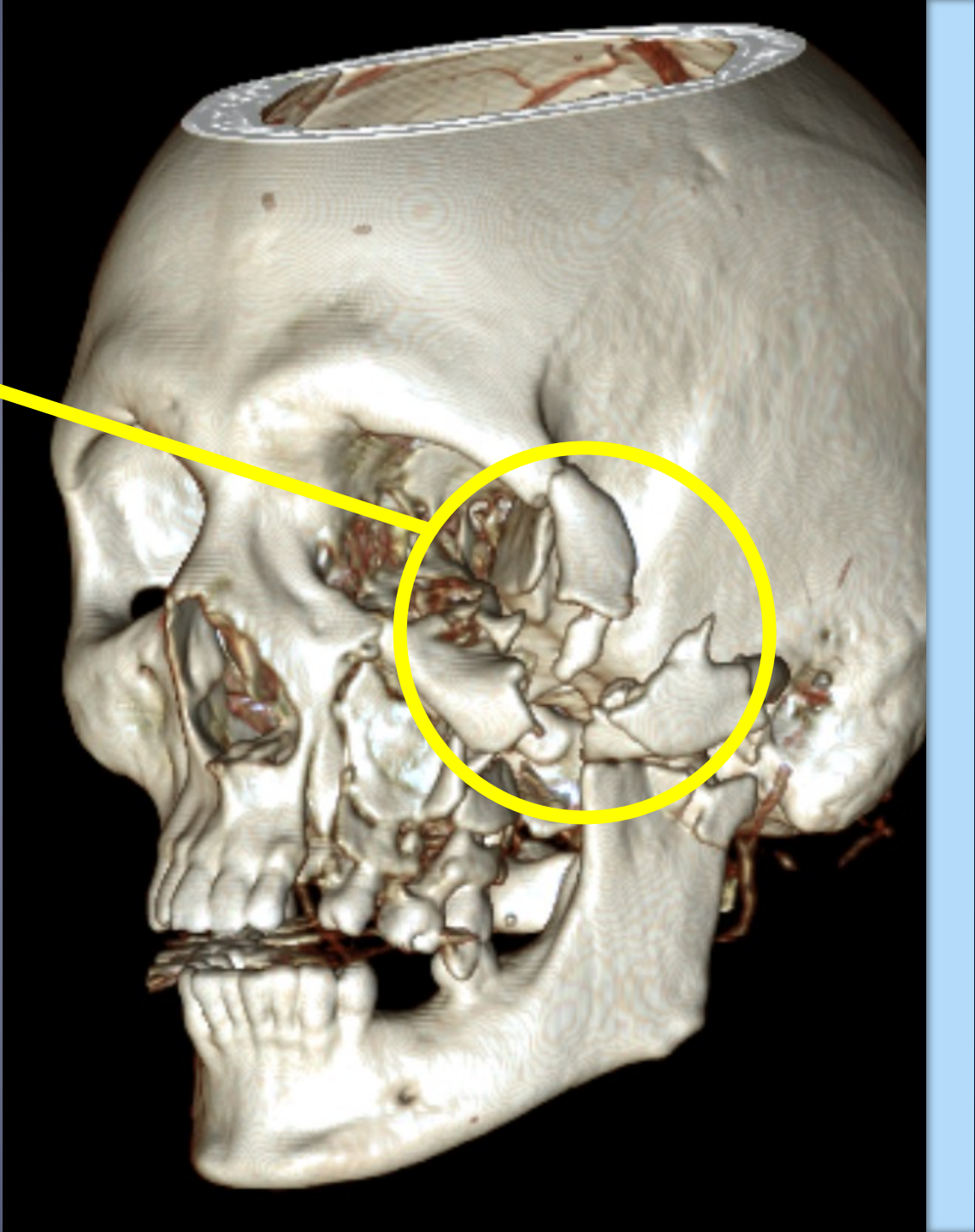
CRAI



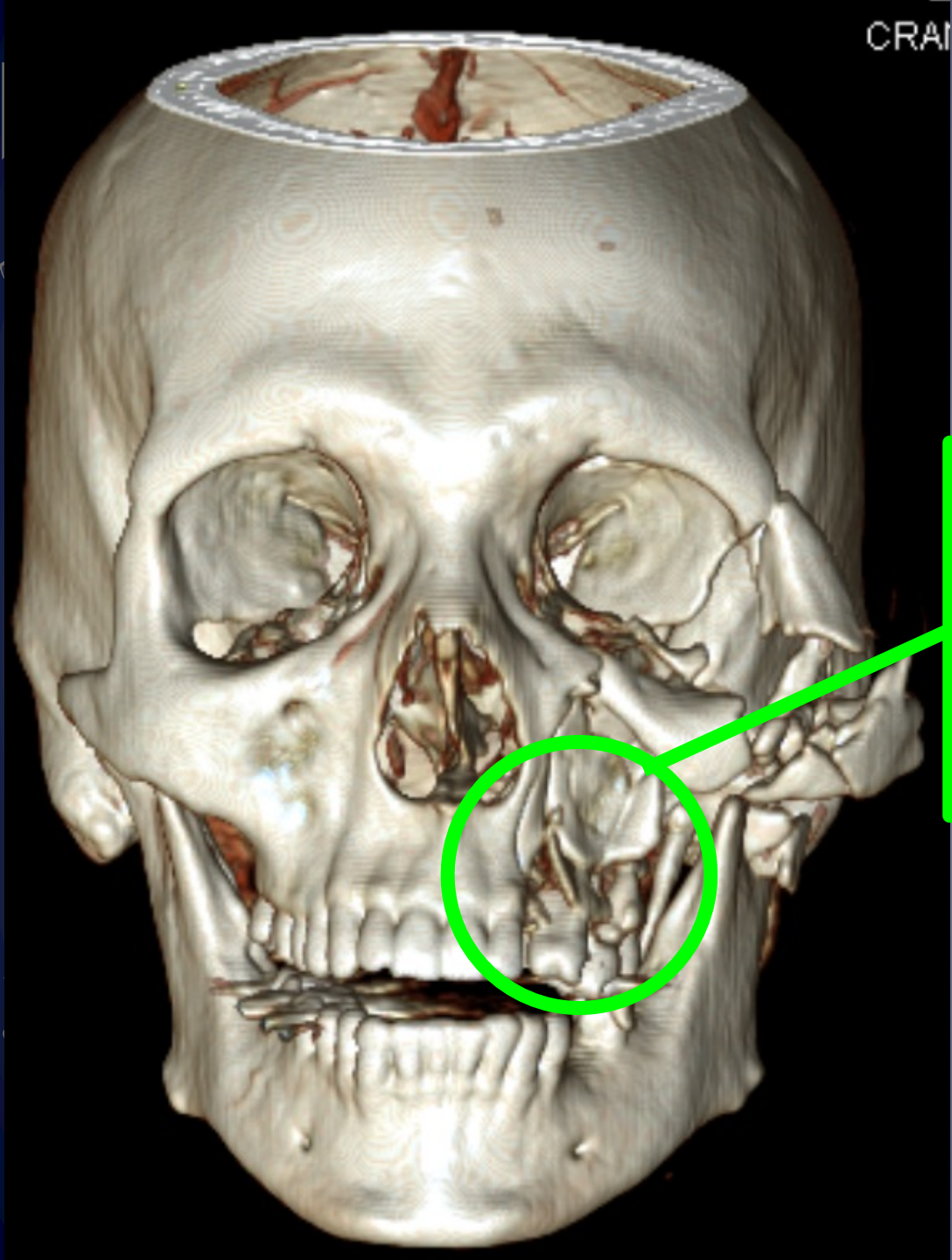
CRAI



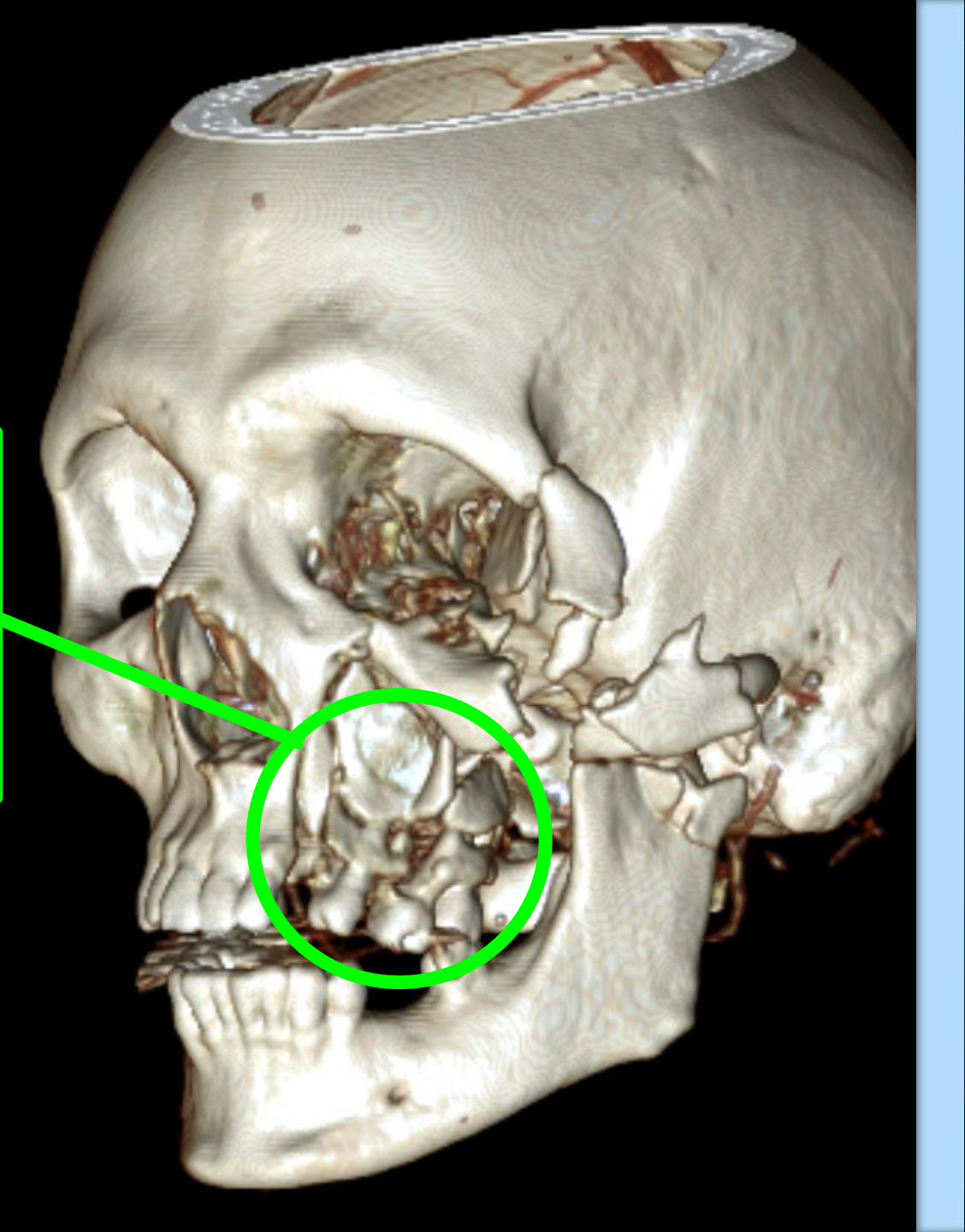
ZMC



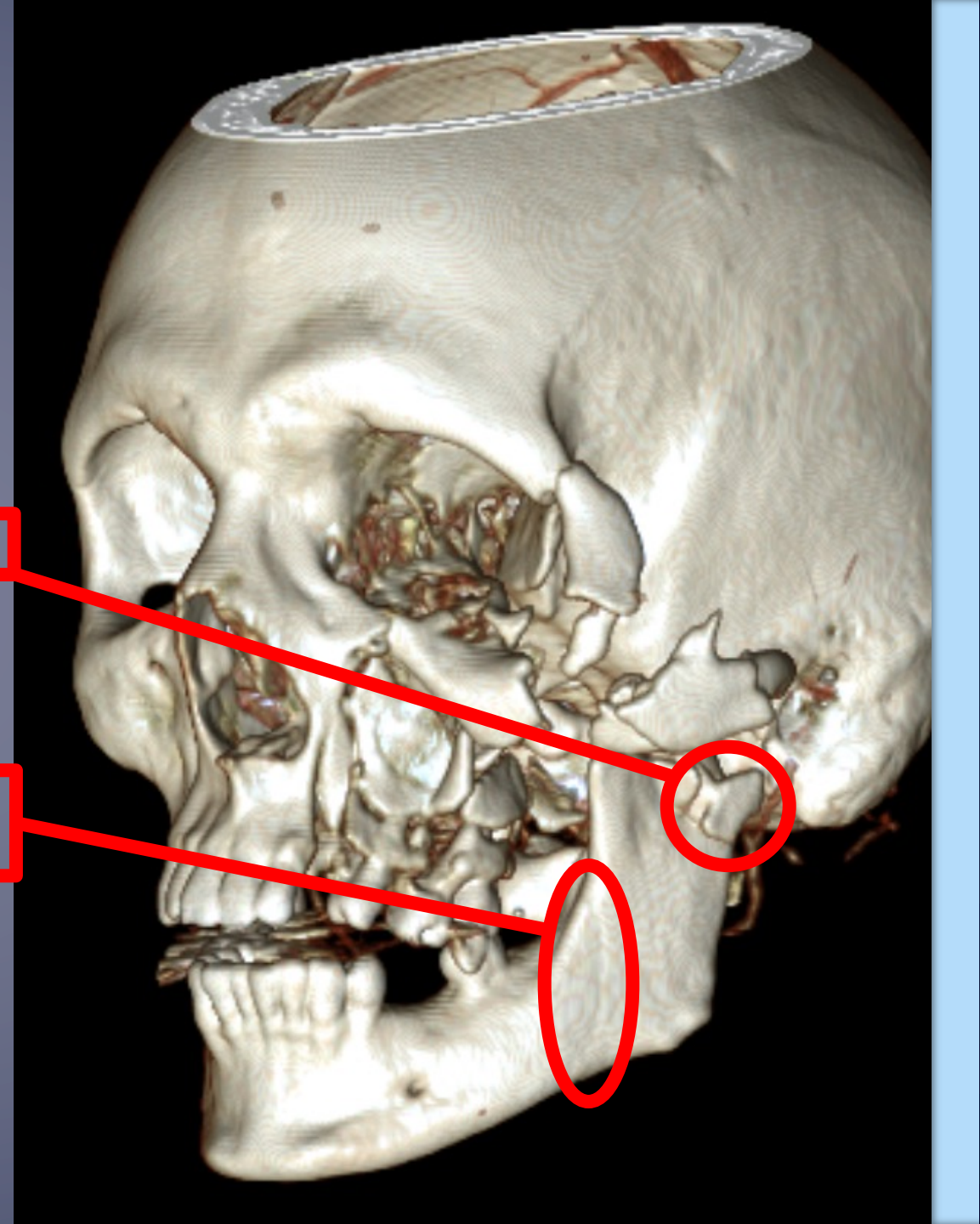
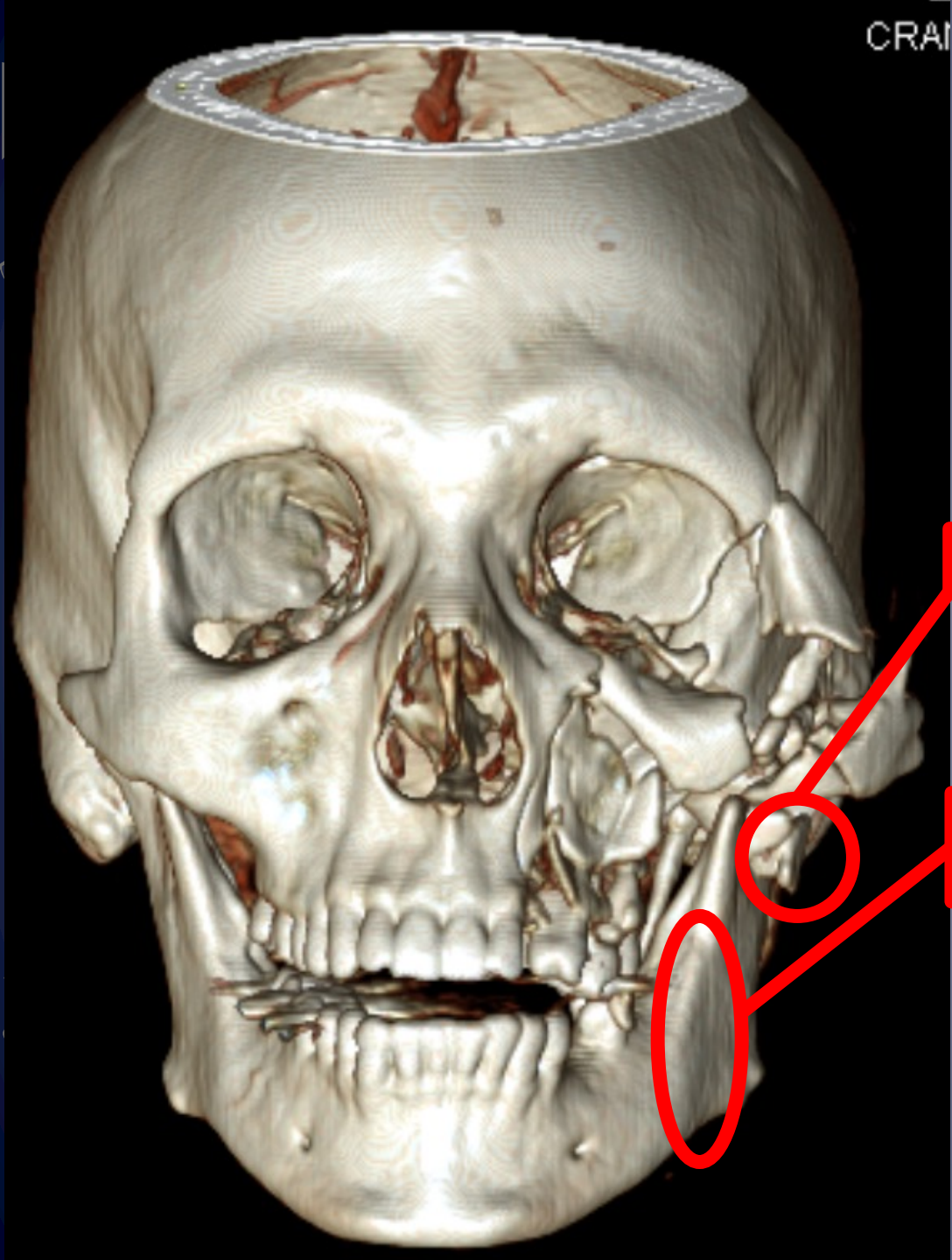
CRAI



Hemi-
Lefort I
+
Alveolar
Fracture

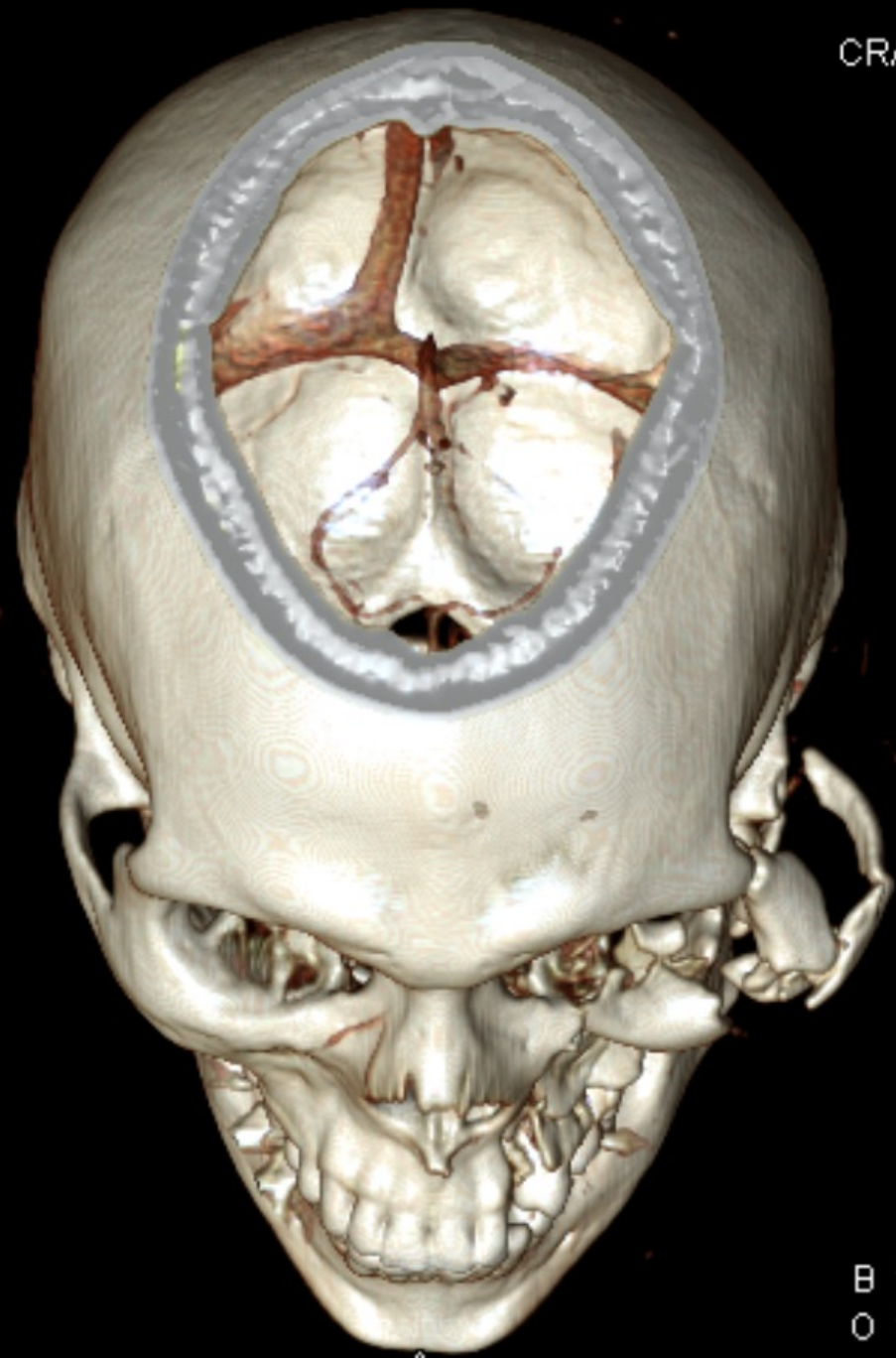



CRAI



Subcondylar

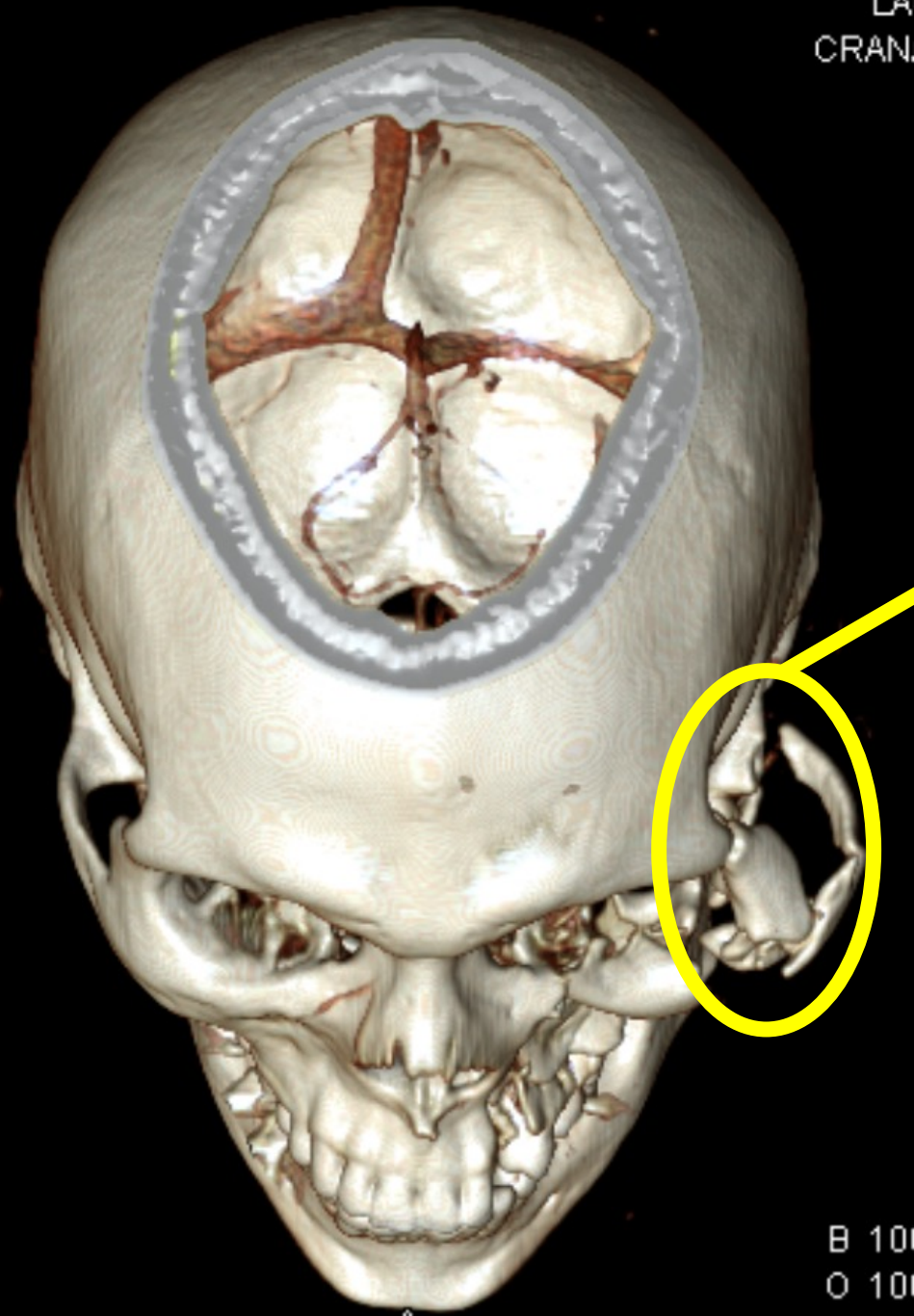

Angle Fracture



RES/CG/93
LA
CRAN.

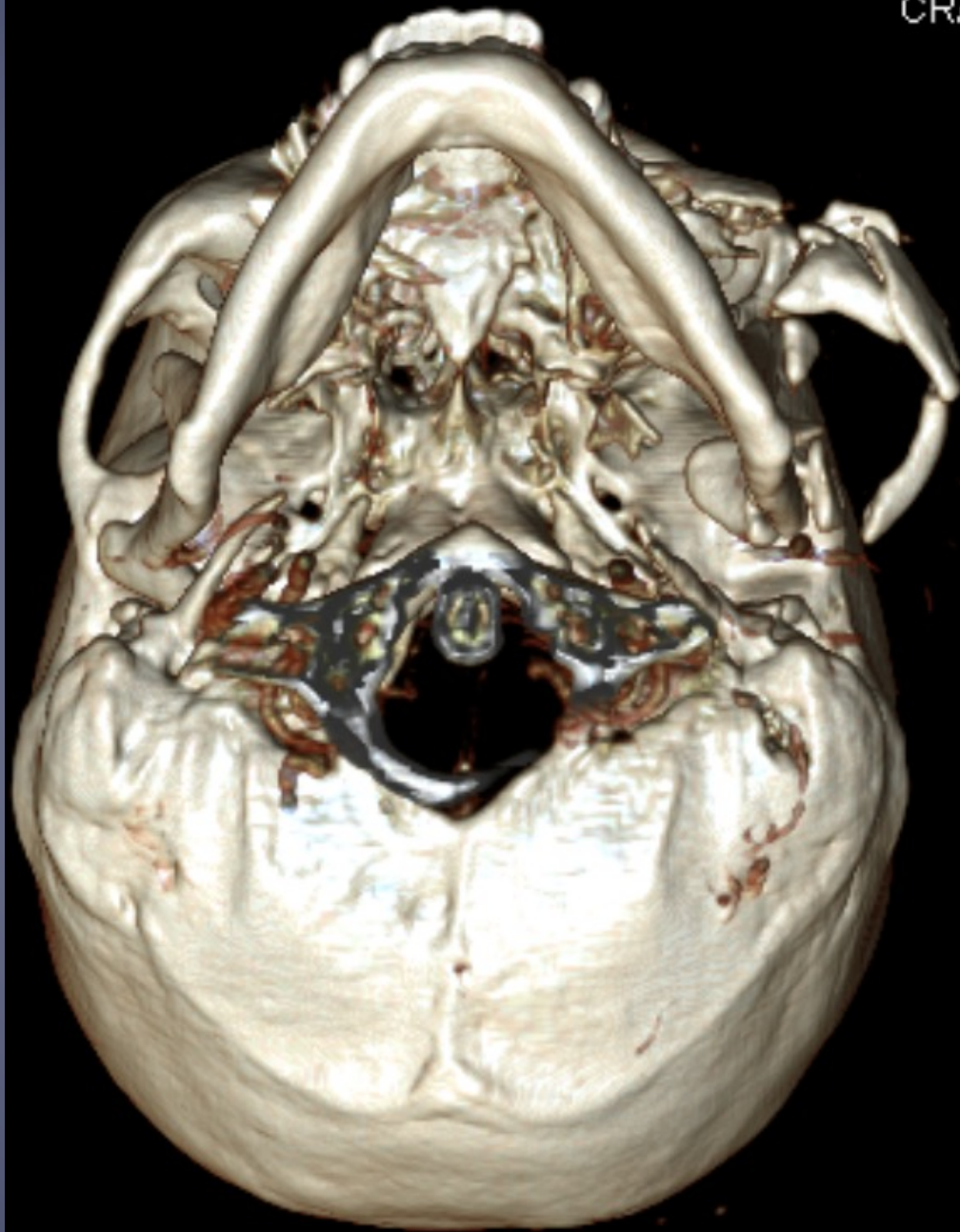
B 10
O 10

A



Comminuted Arch

华中科技大学

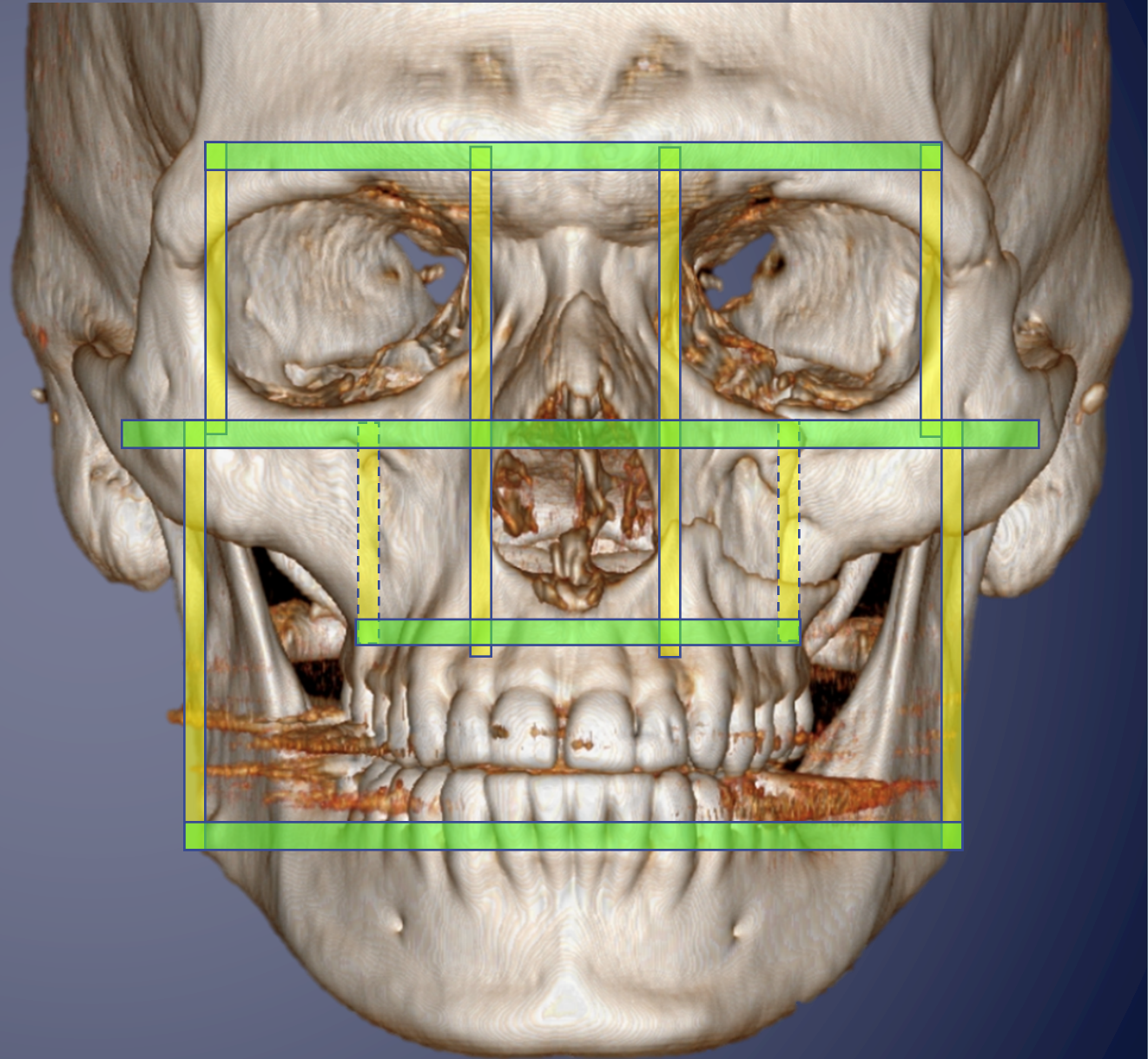
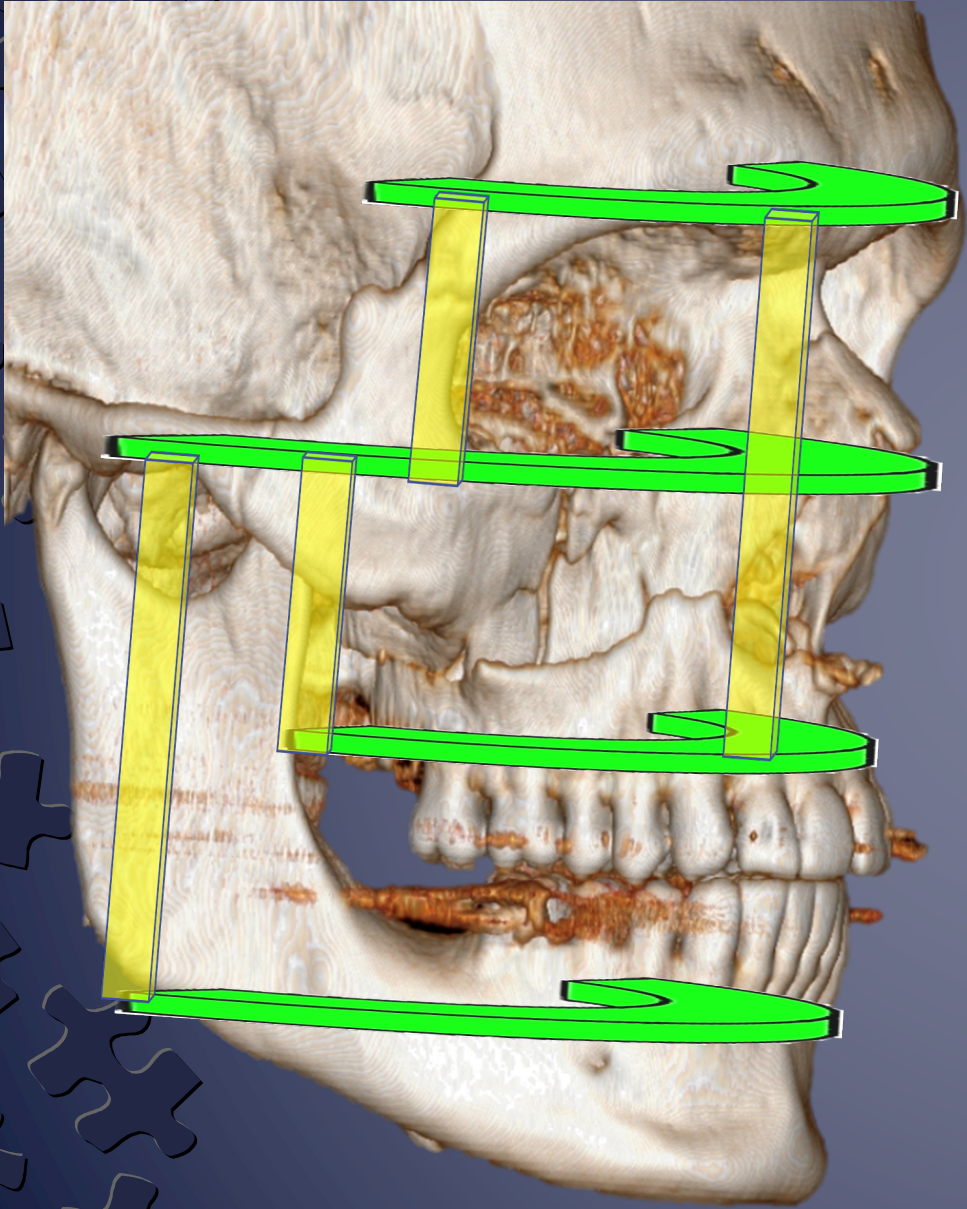


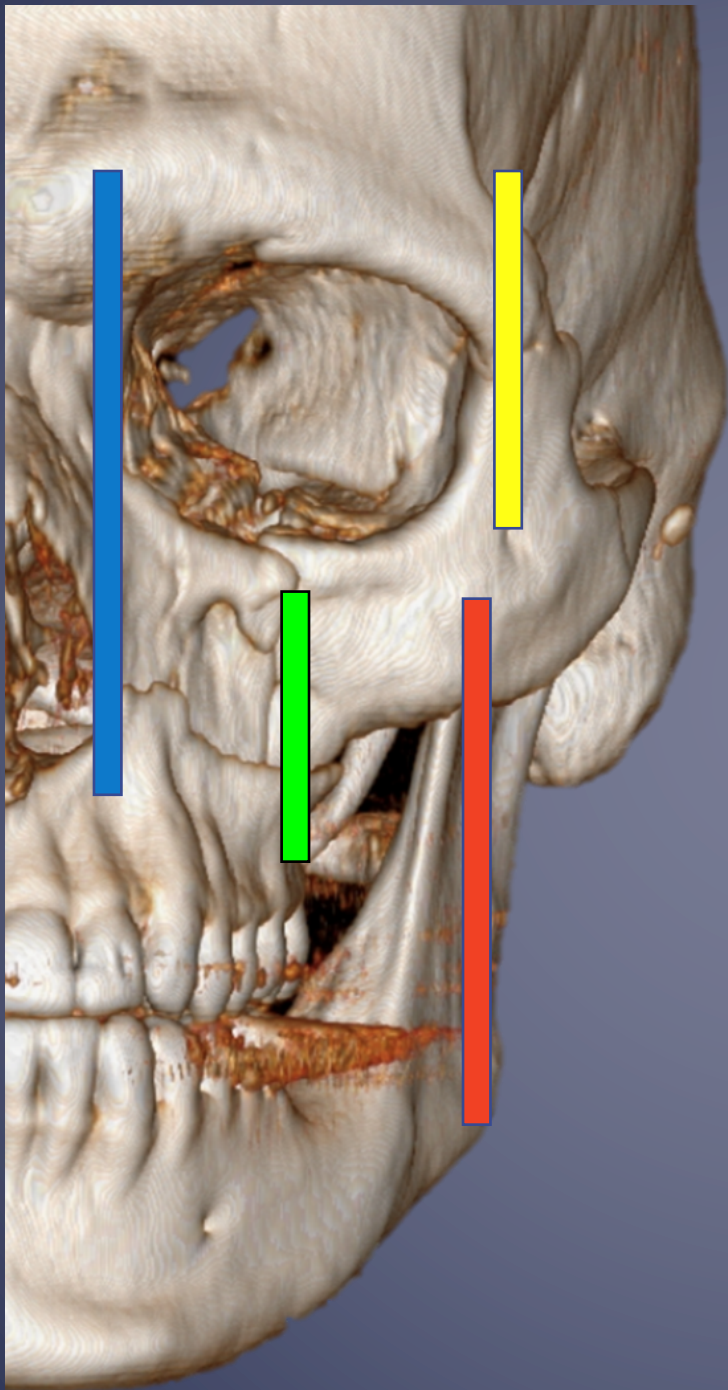
L
CRAI

Fracture Summary → Status

- › ZMC-----→ Severe Comminution/Displacement
- › Zygomatic Arch-----→ Severe Comminution/Displacement
- › Orbital Floor-----→ Displaced
- › Hemi-Lefort-----→ Comminuted
- › Dentoalveolar-----→ Comminuted
- › Subcondylar-----→ Displaced and Mildly Comminuted
- › Mandibular Angle----→ Non-displaced

Facial Buttresses





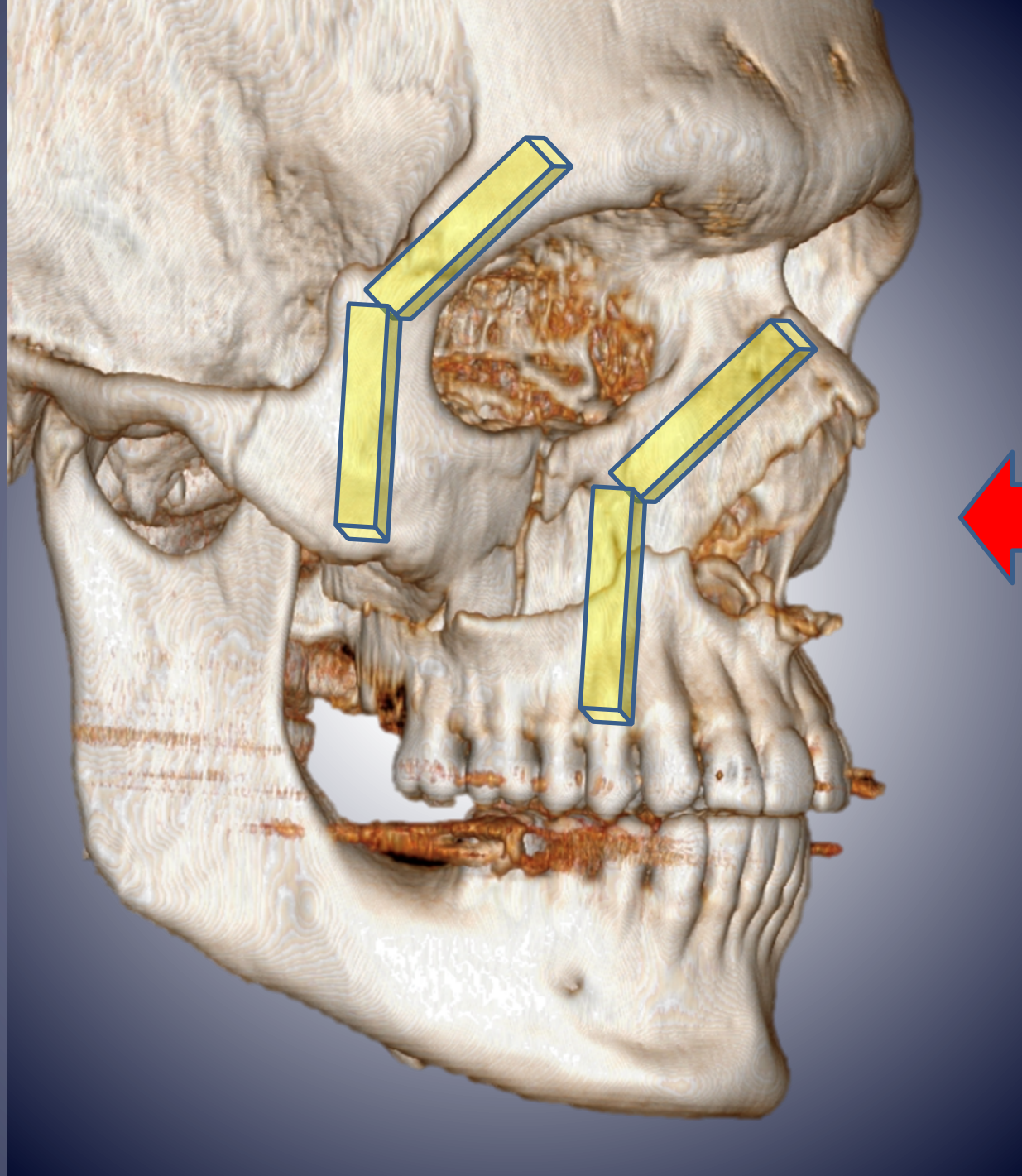

Vertical Buttresses

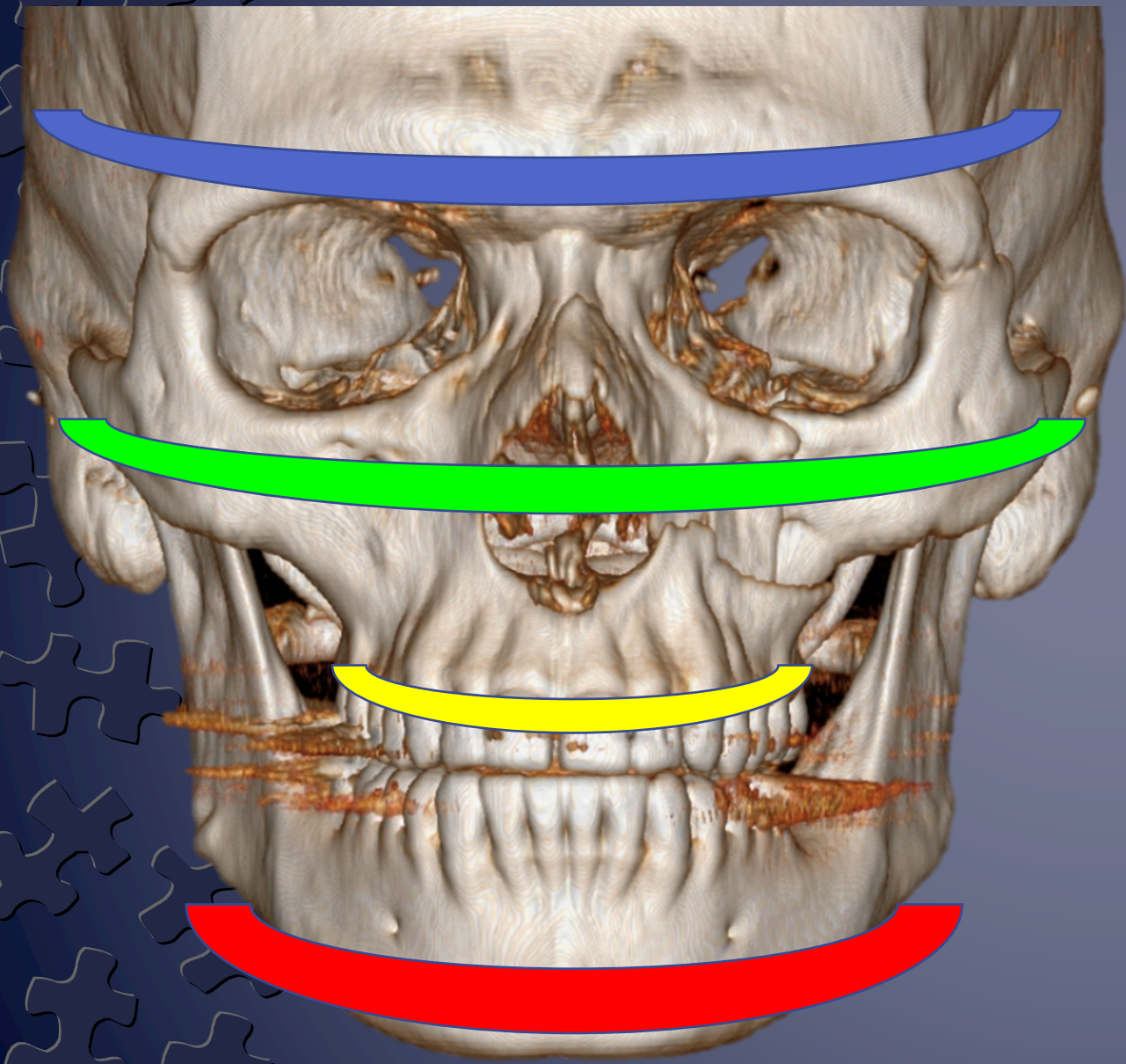
Piriform Rim

Zygomatic Buttress

Zygomatico Frontal

Mandibular Ramus





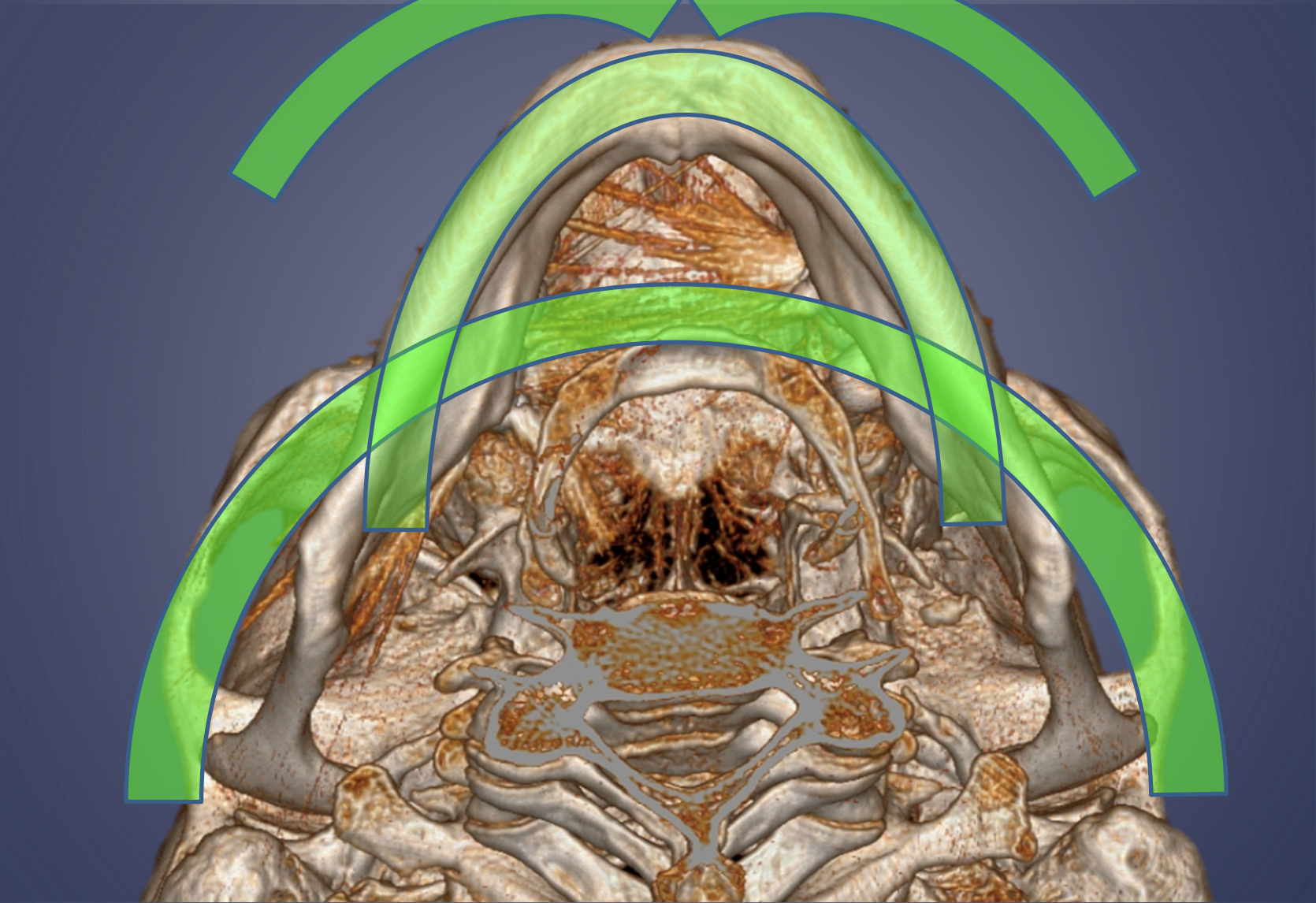

Horizontal Buttresses

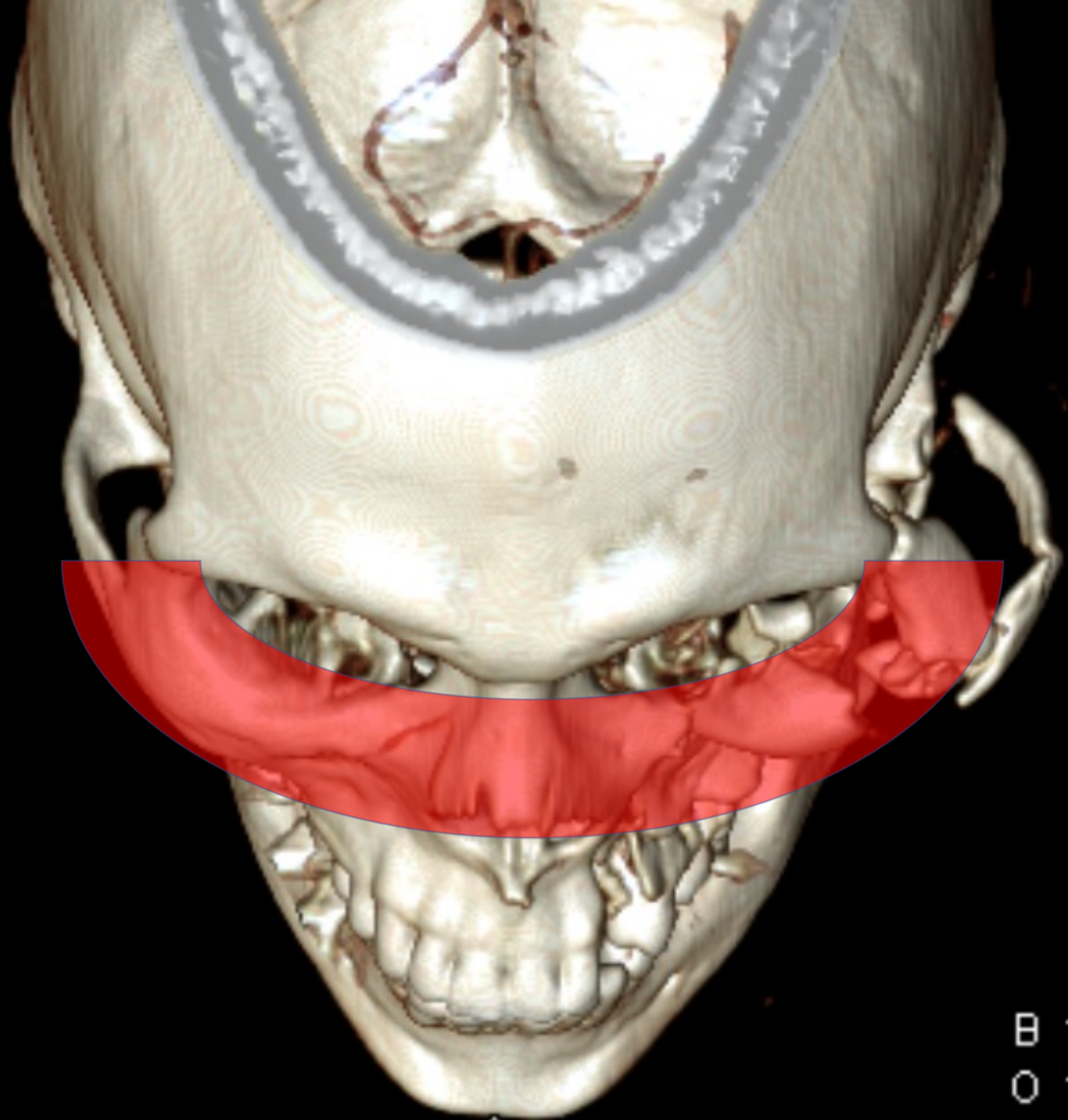

Frontal Bar

Zygoma/Zygomatic Arch

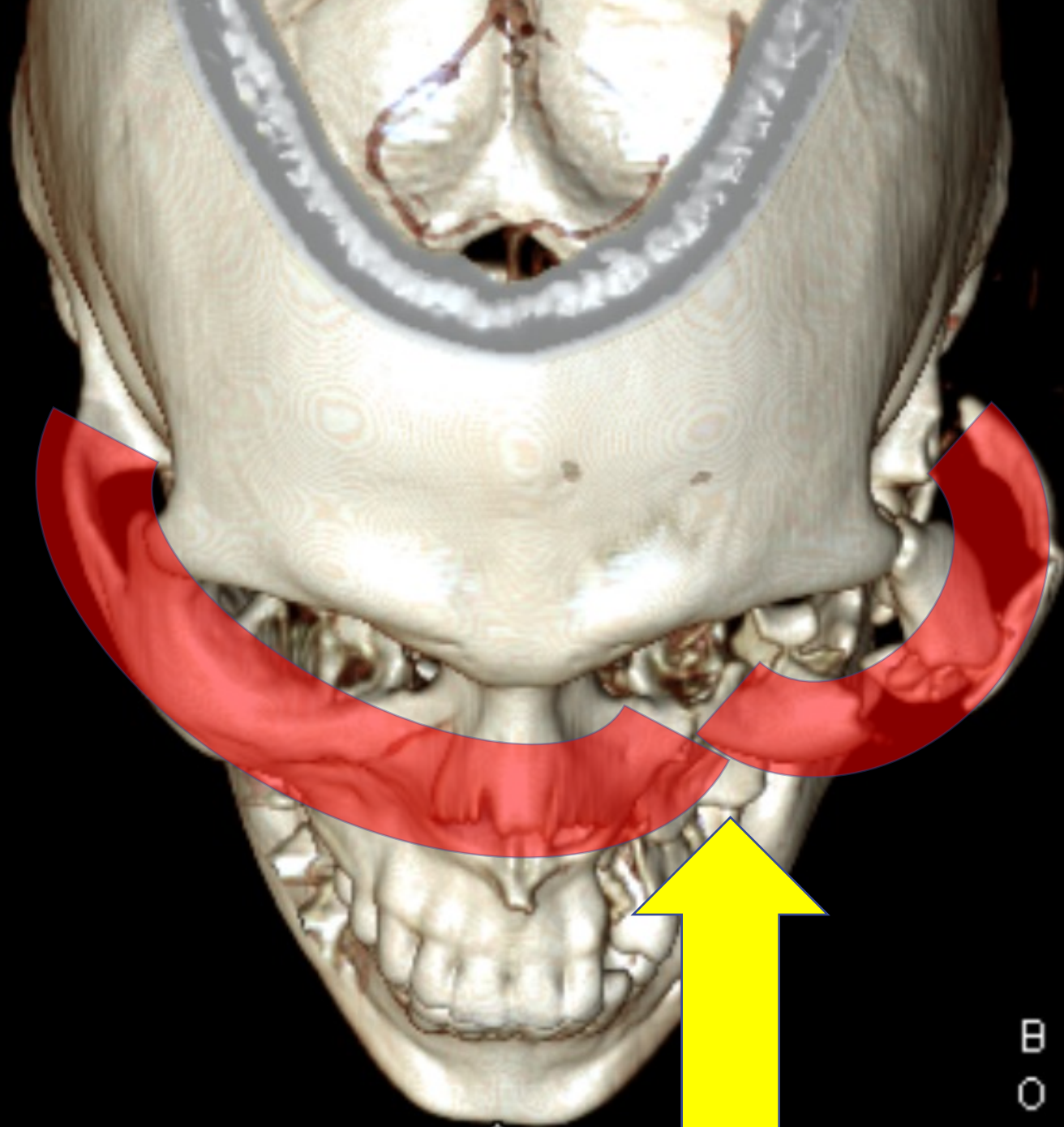

Maxilla

Mandible





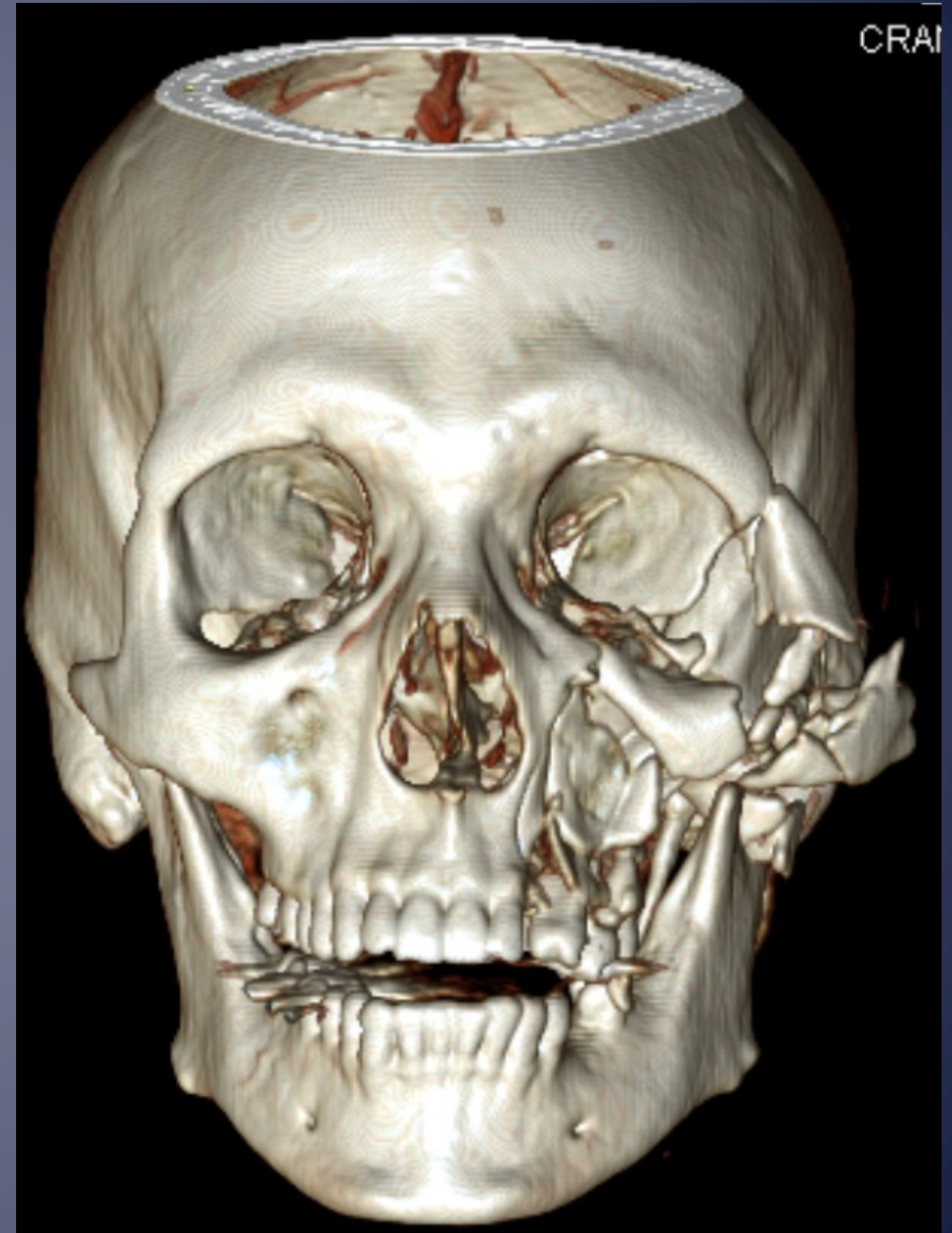B 100
O 100



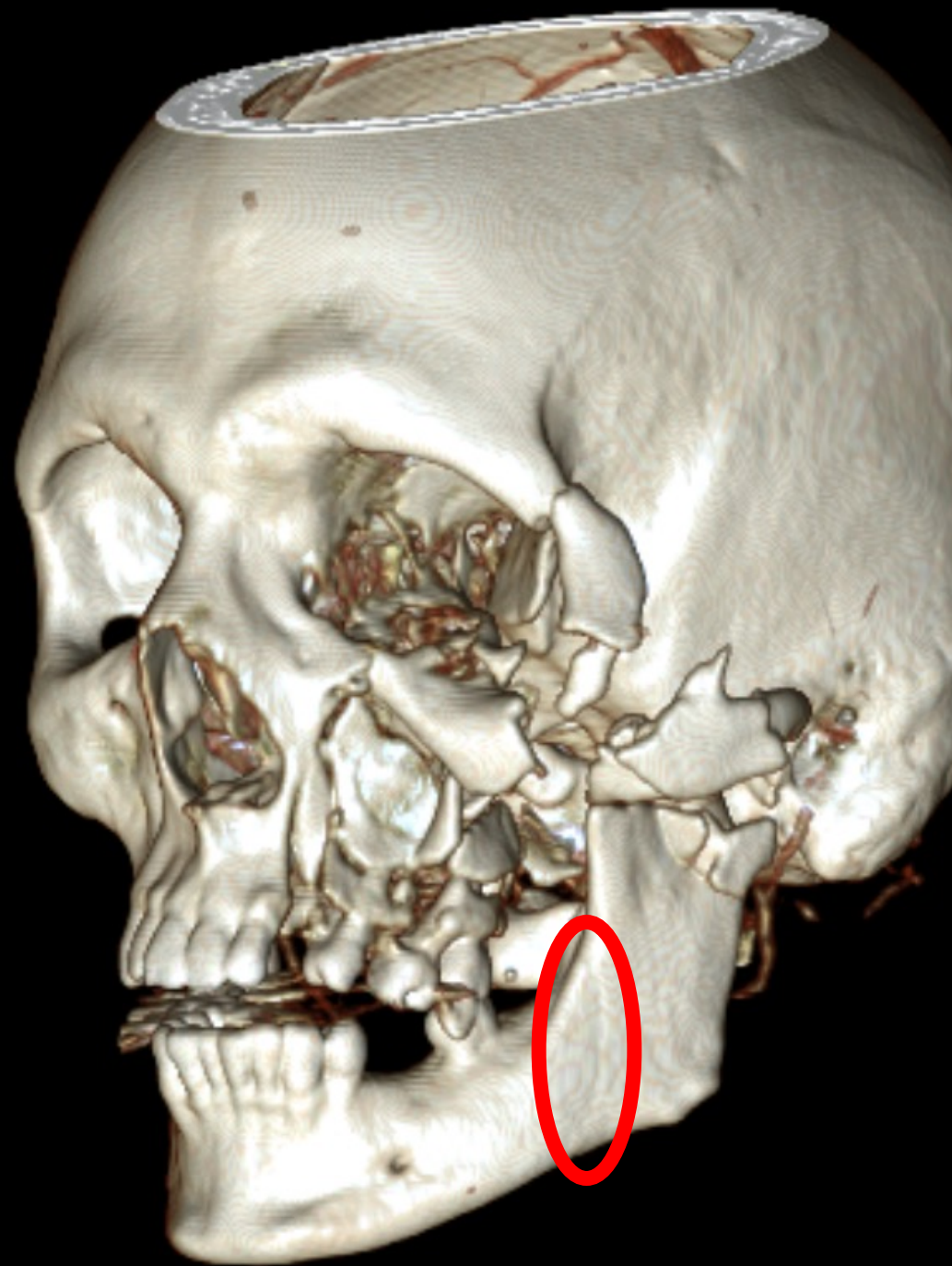
B 100
O 100

Surgical Planning

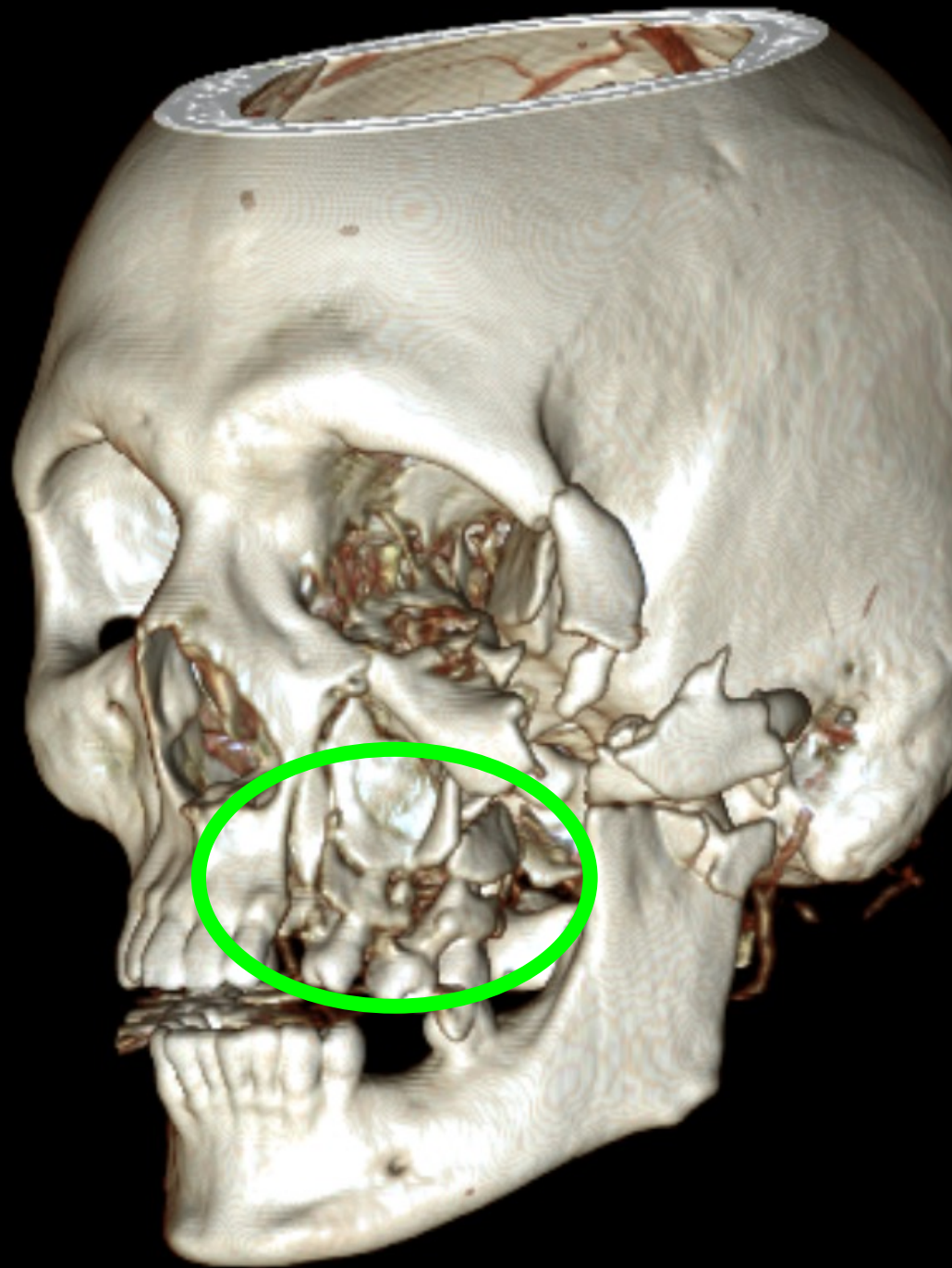
- › Fracture Junction Fixation
- › Approaches
 - Choosing the proper access will determine the ability to adequately reduce fractures.
 - Guided by degree of displacement and overall severity of fractures.
- › Sequencing
 - Top down
 - Out to in



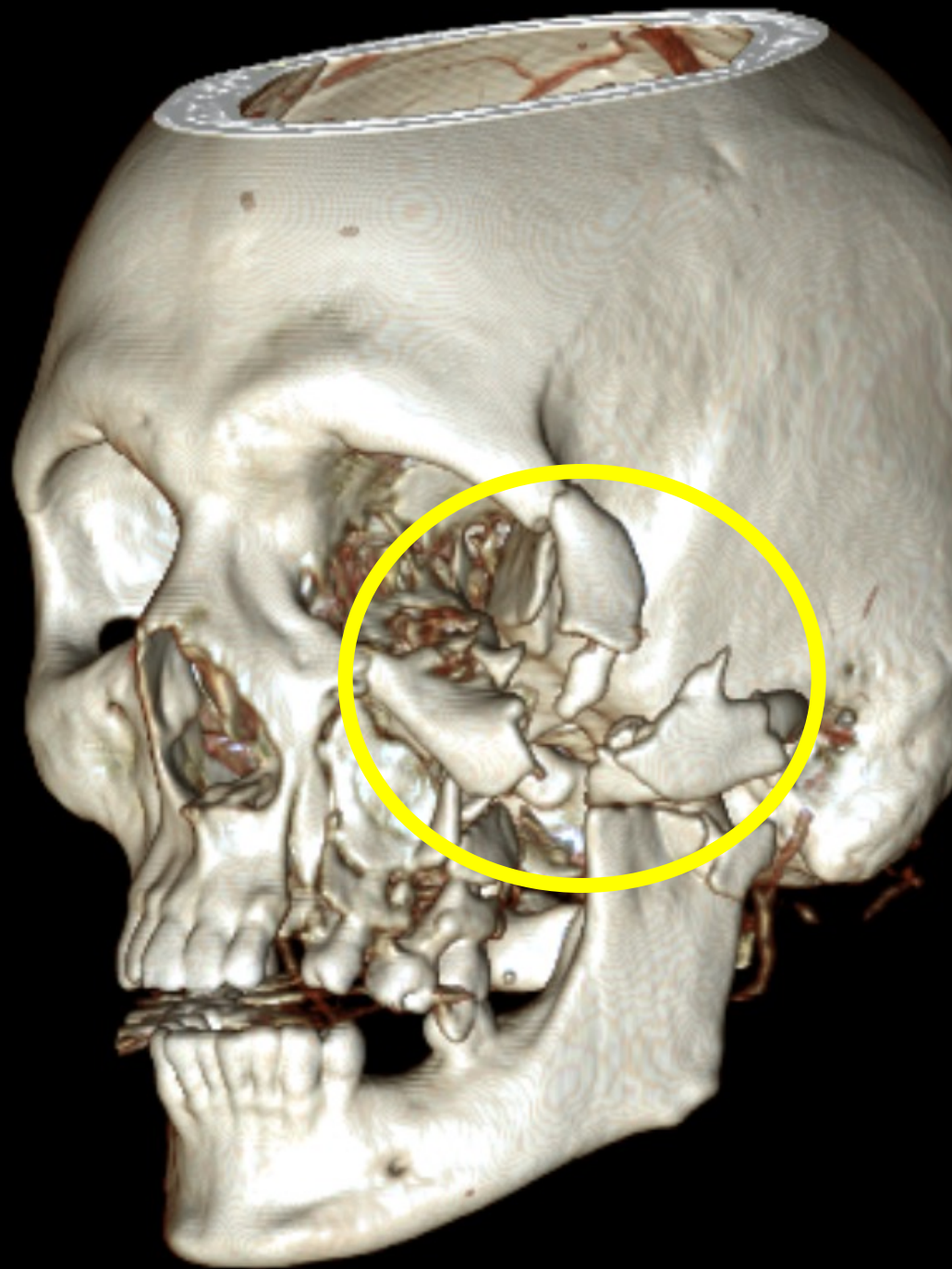
Left Angle



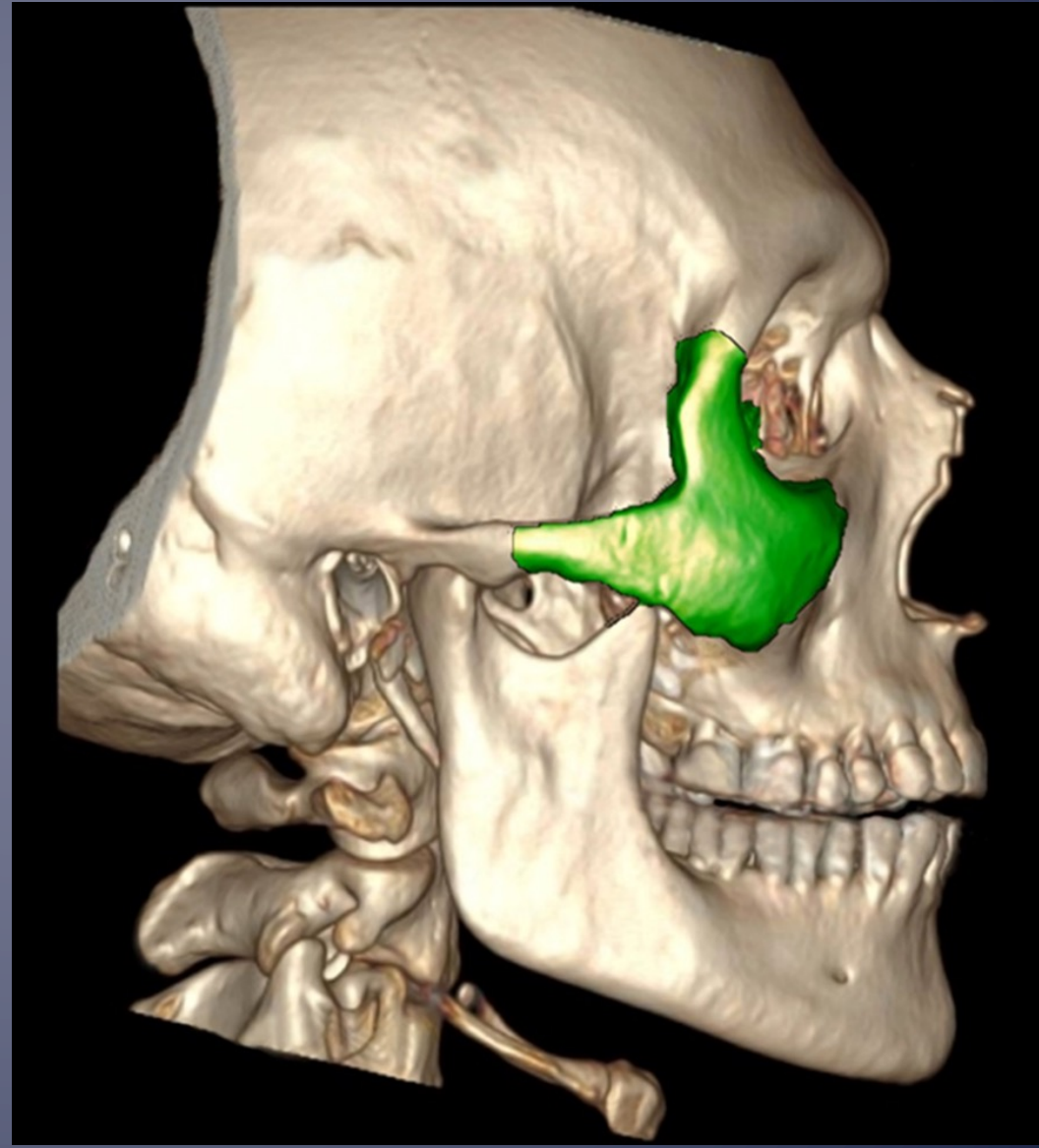
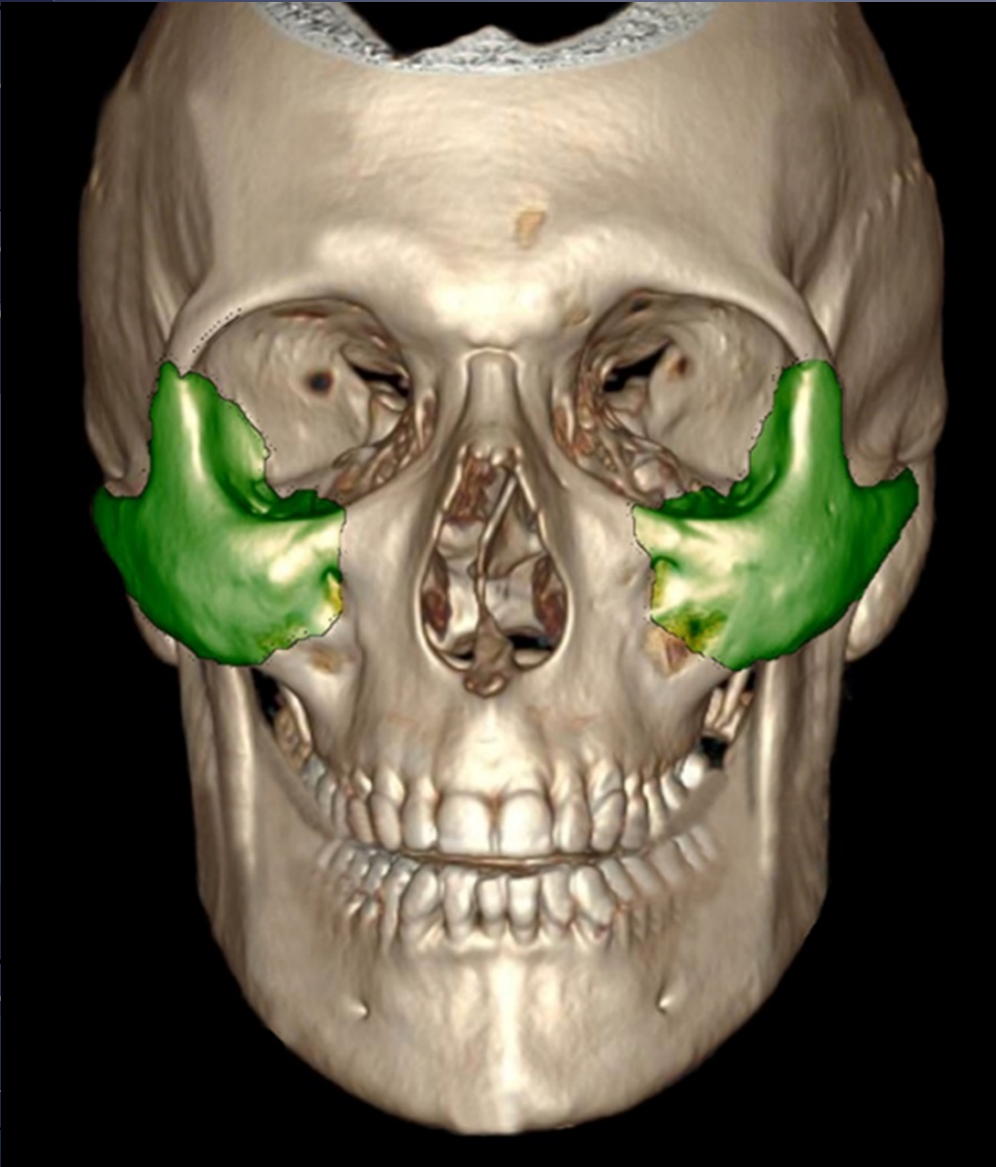Left Maxilla

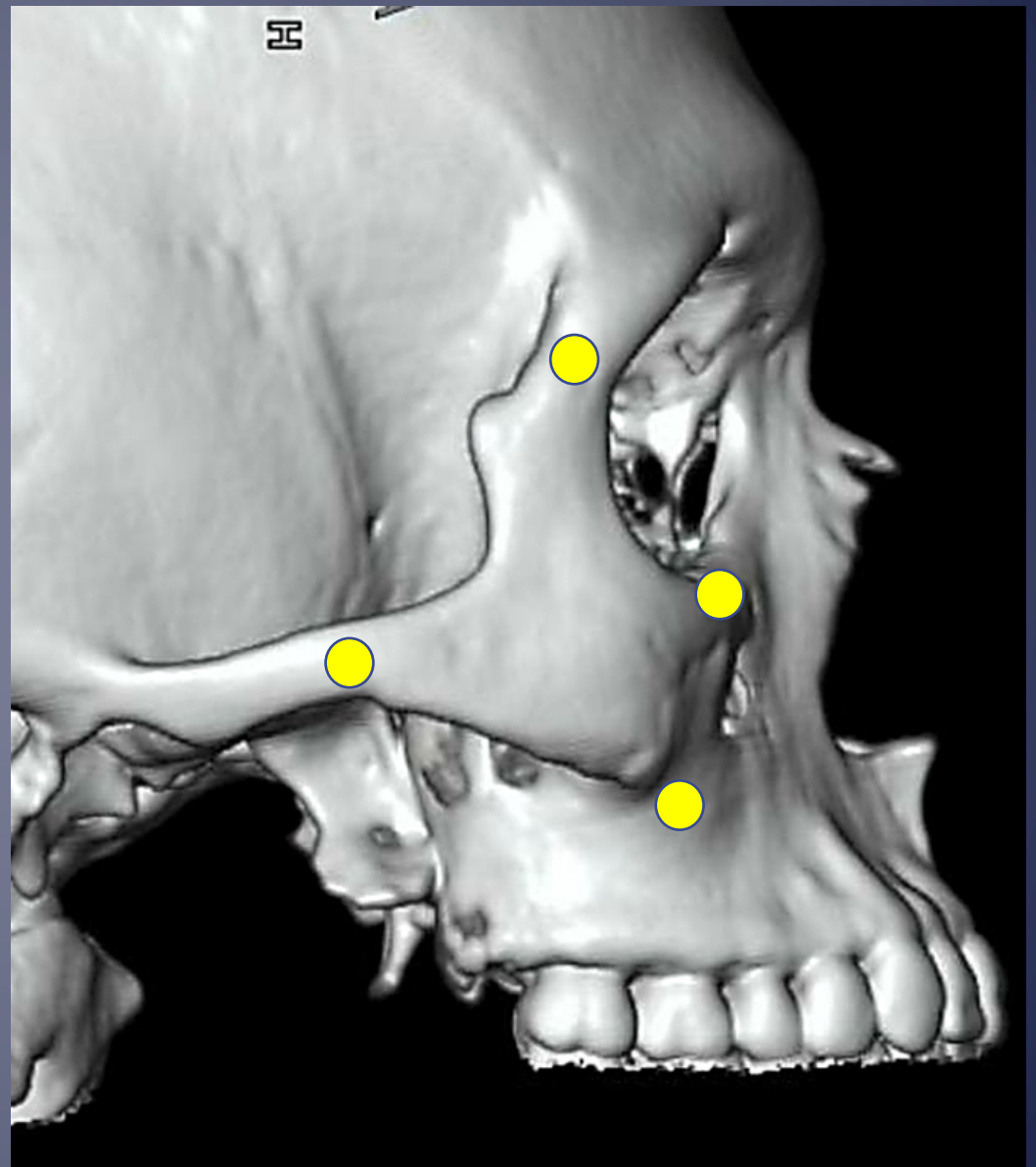
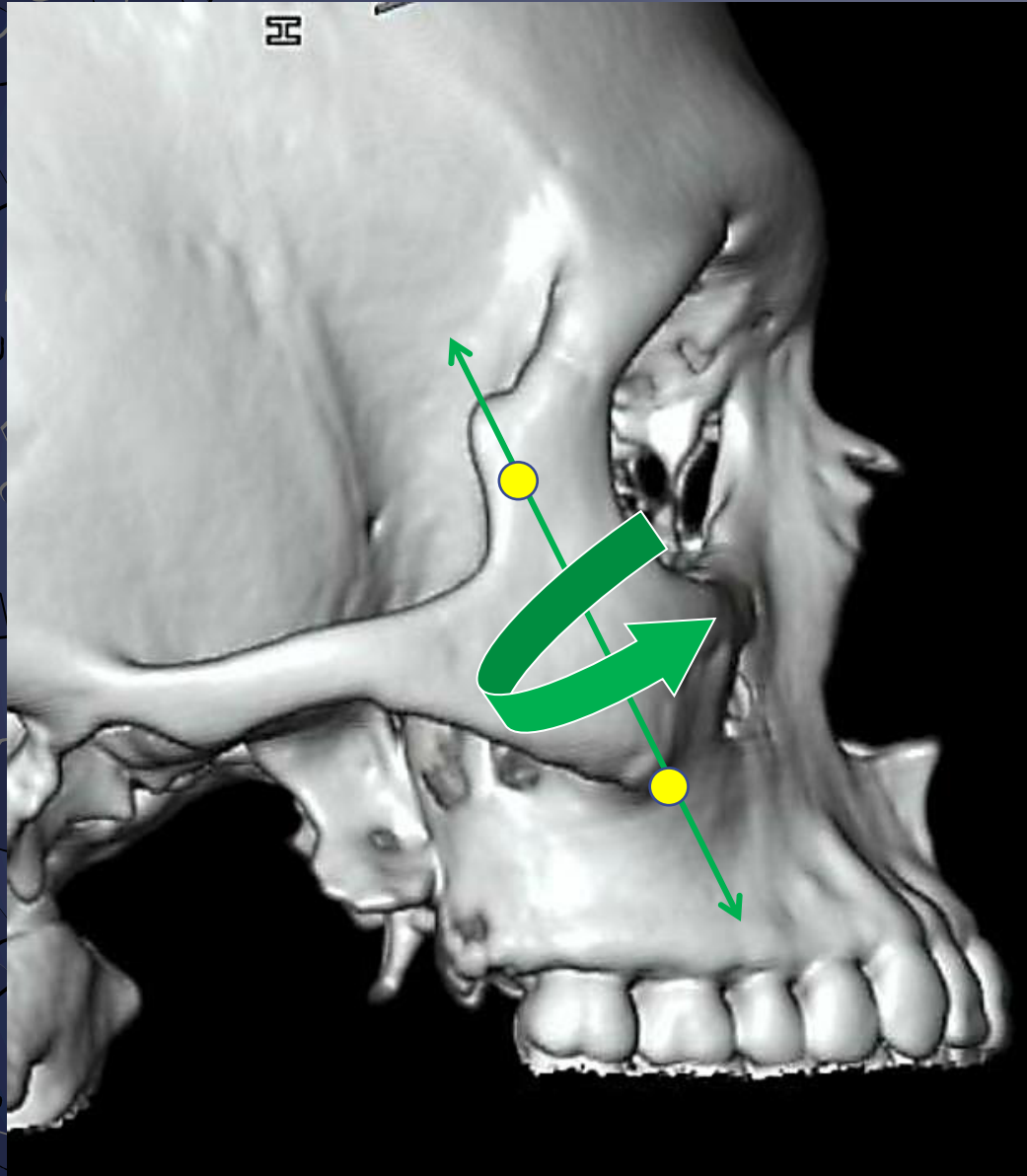


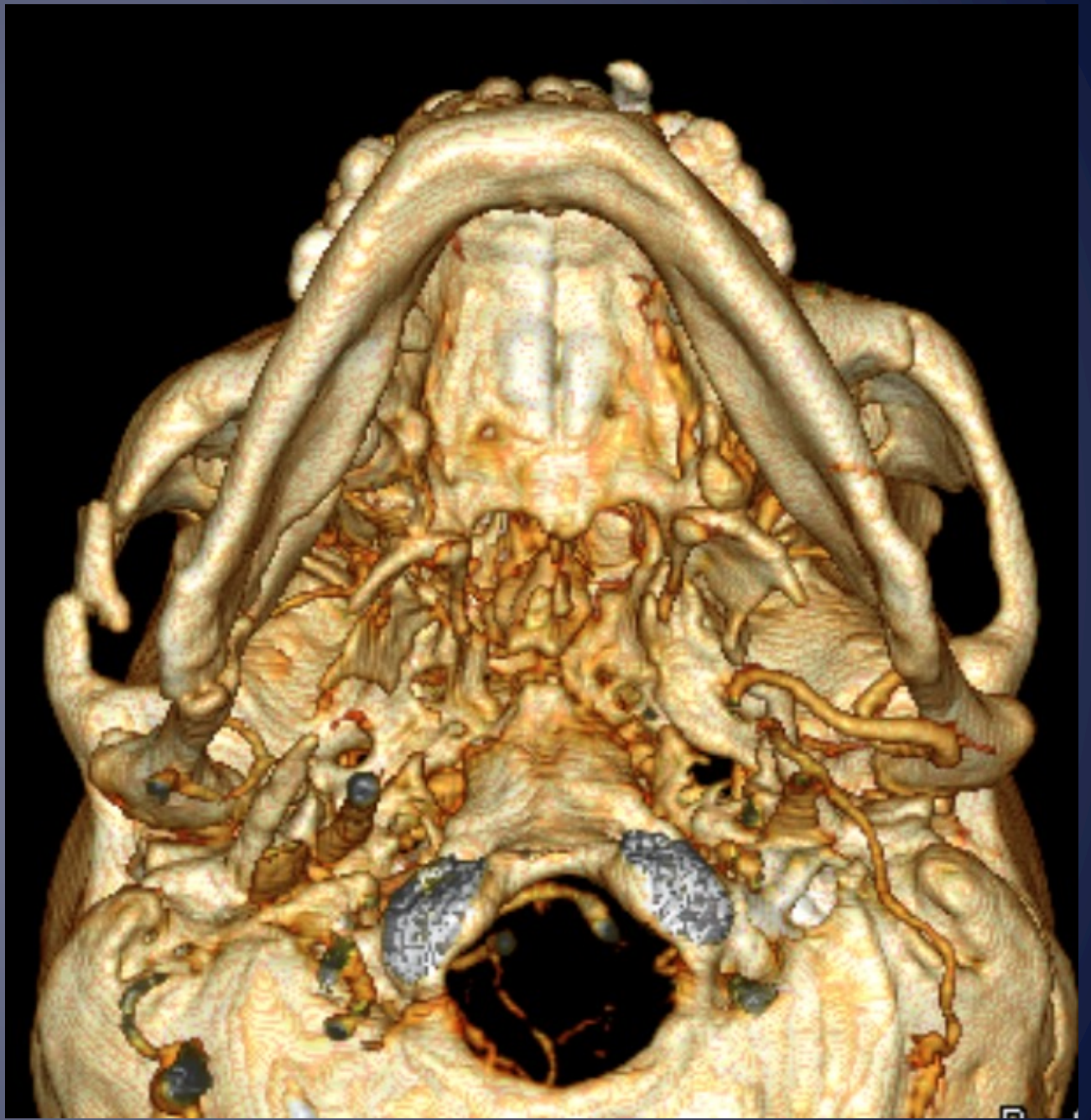
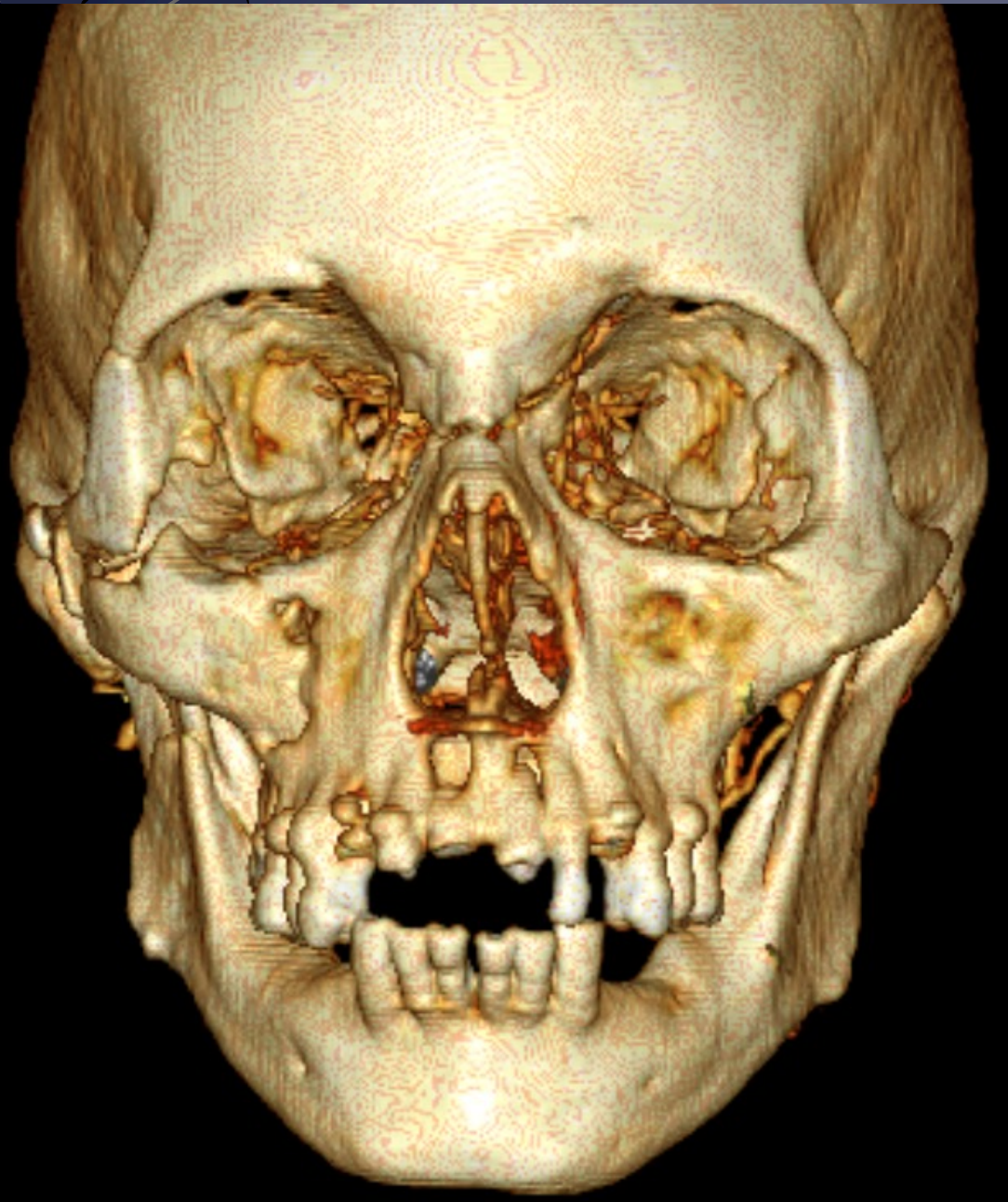
Left ZMC

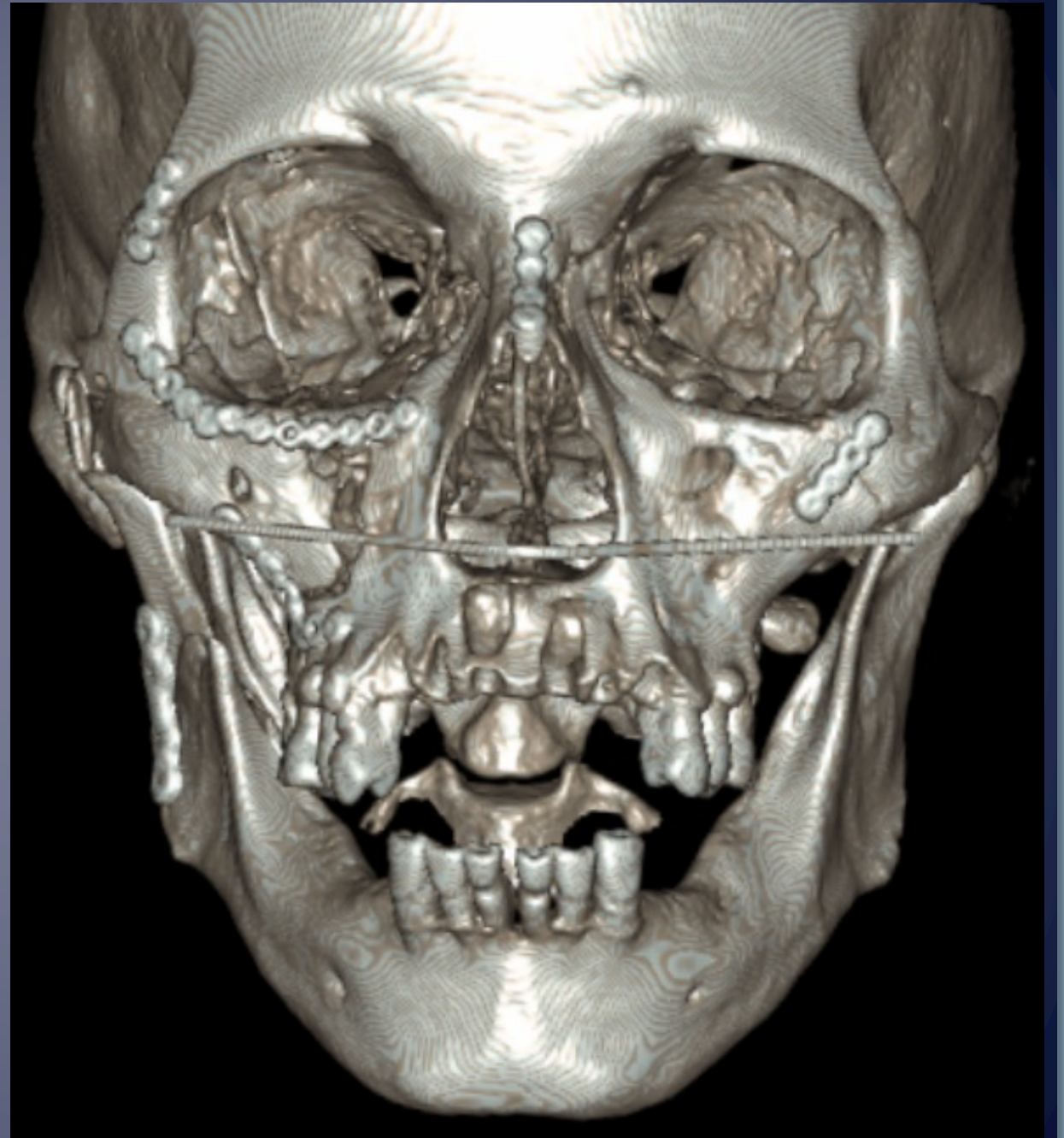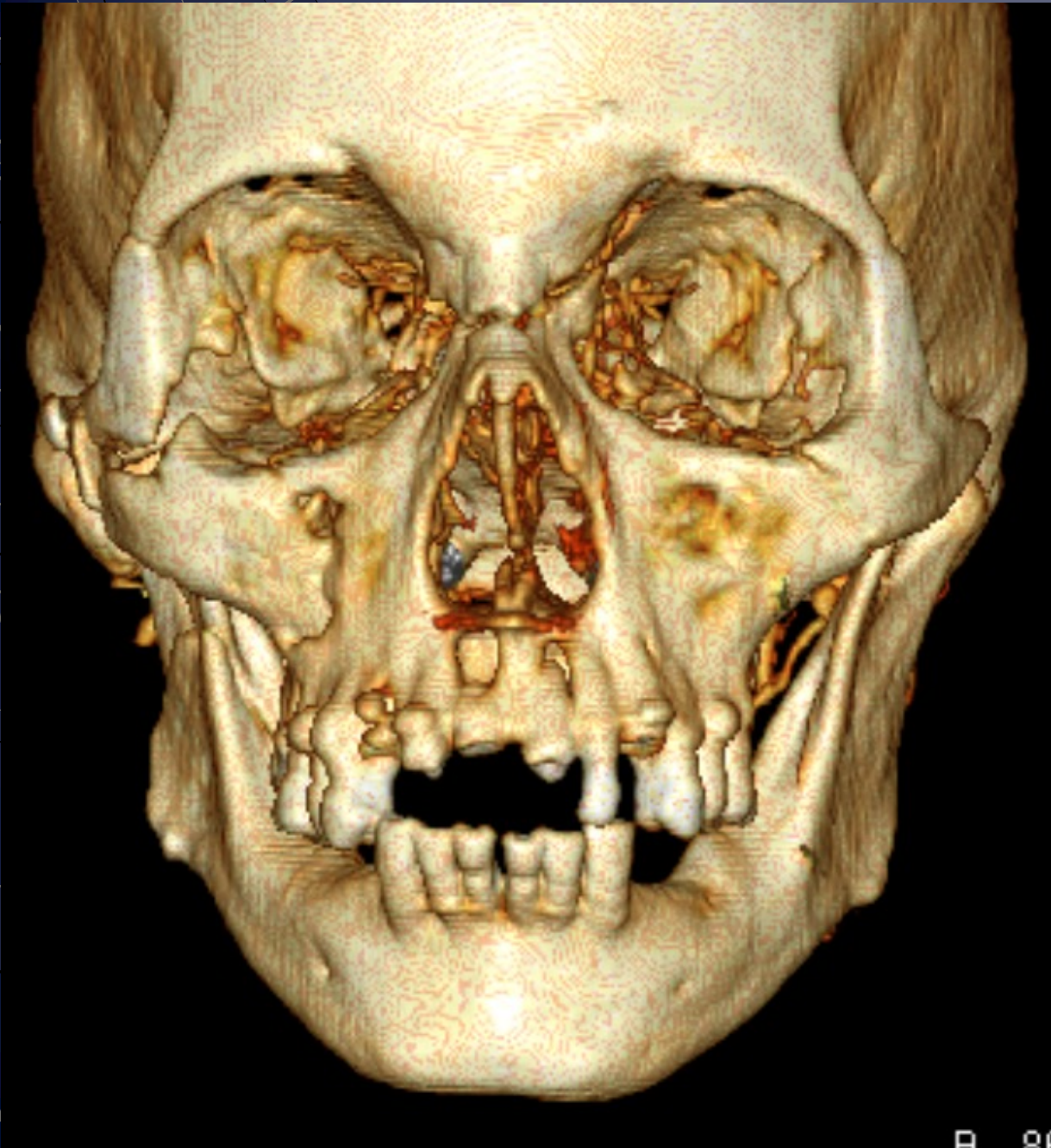


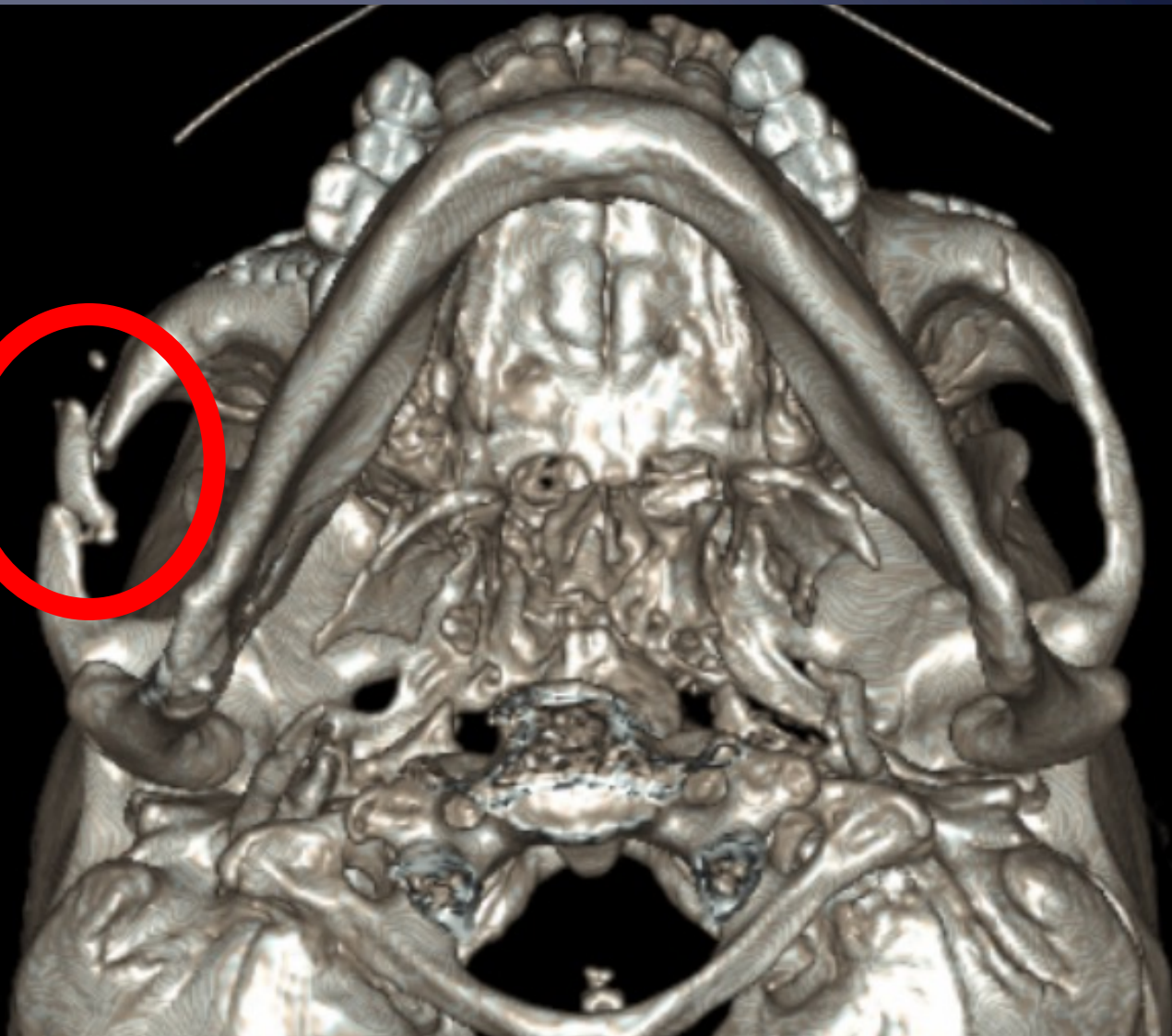
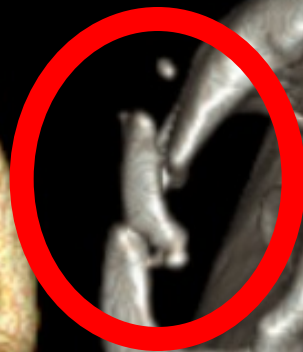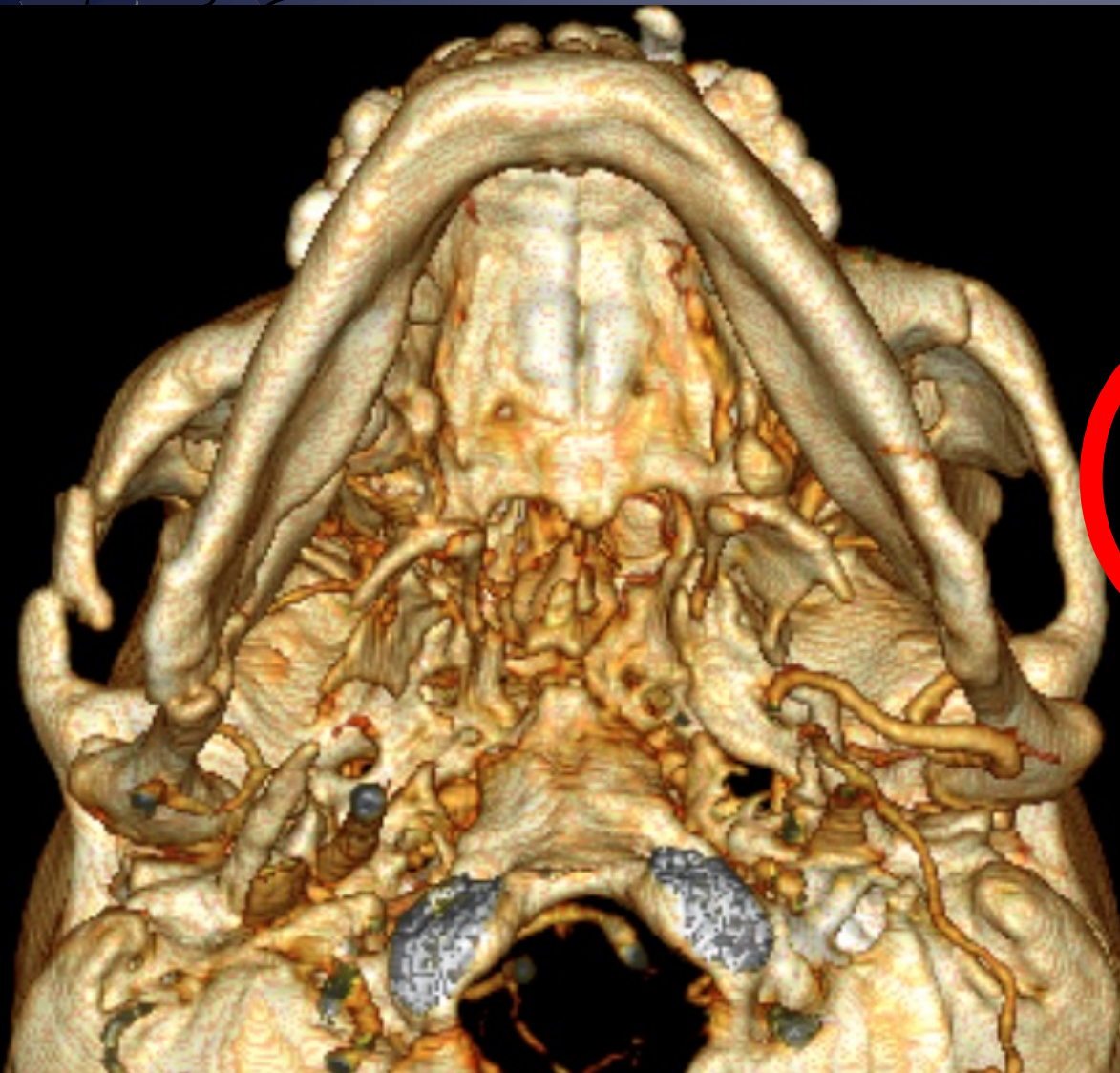Zygomaticomaxillary Complex



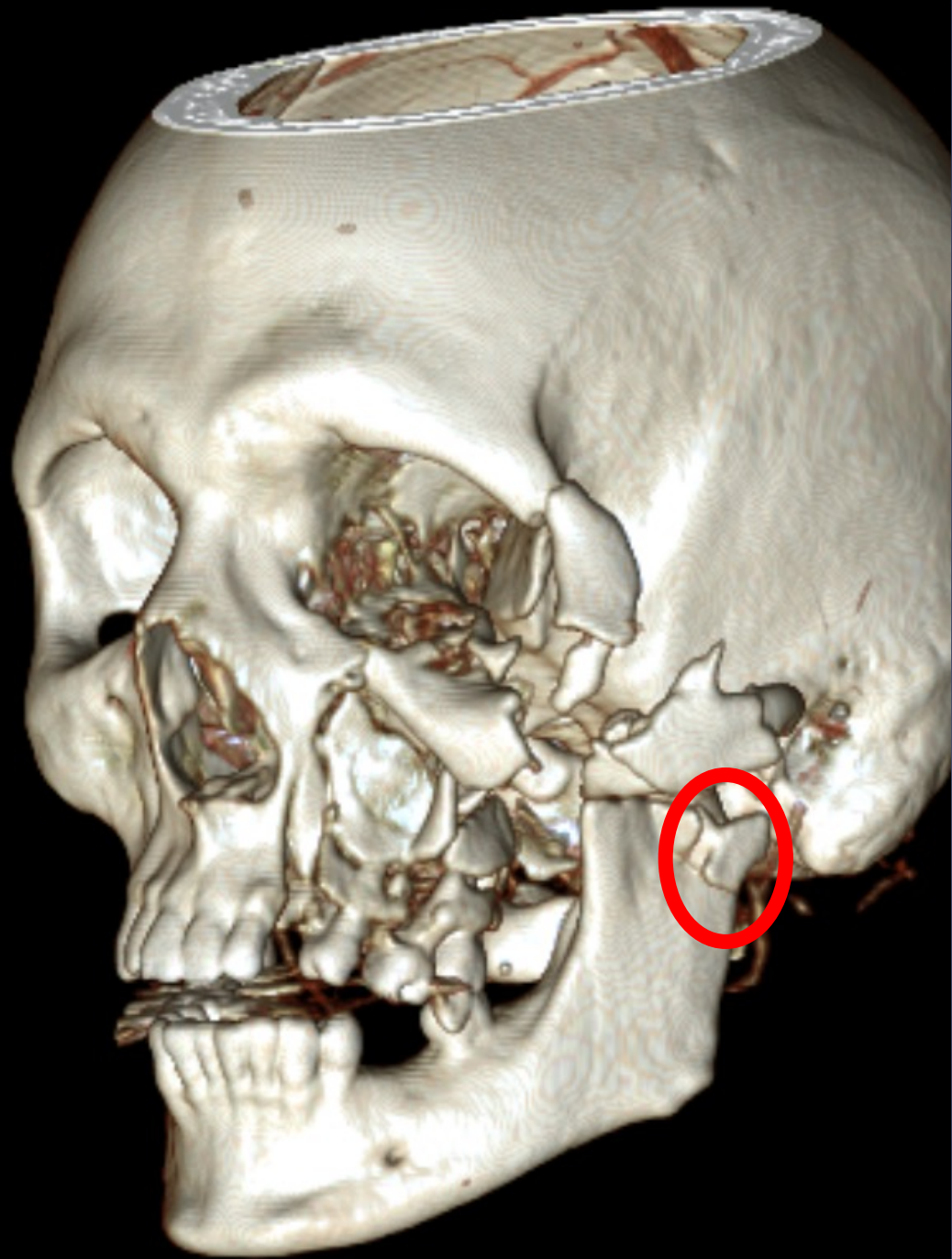




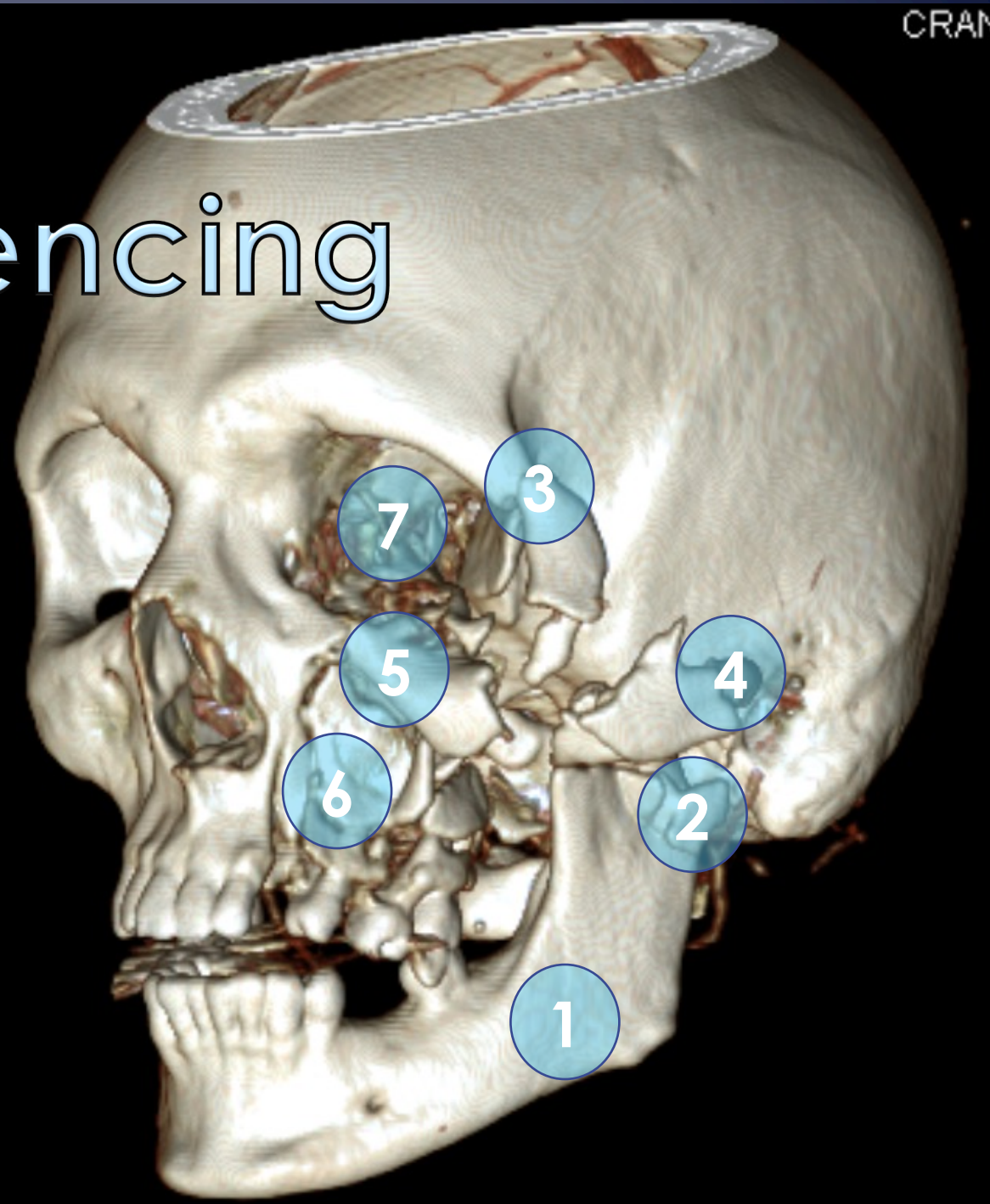
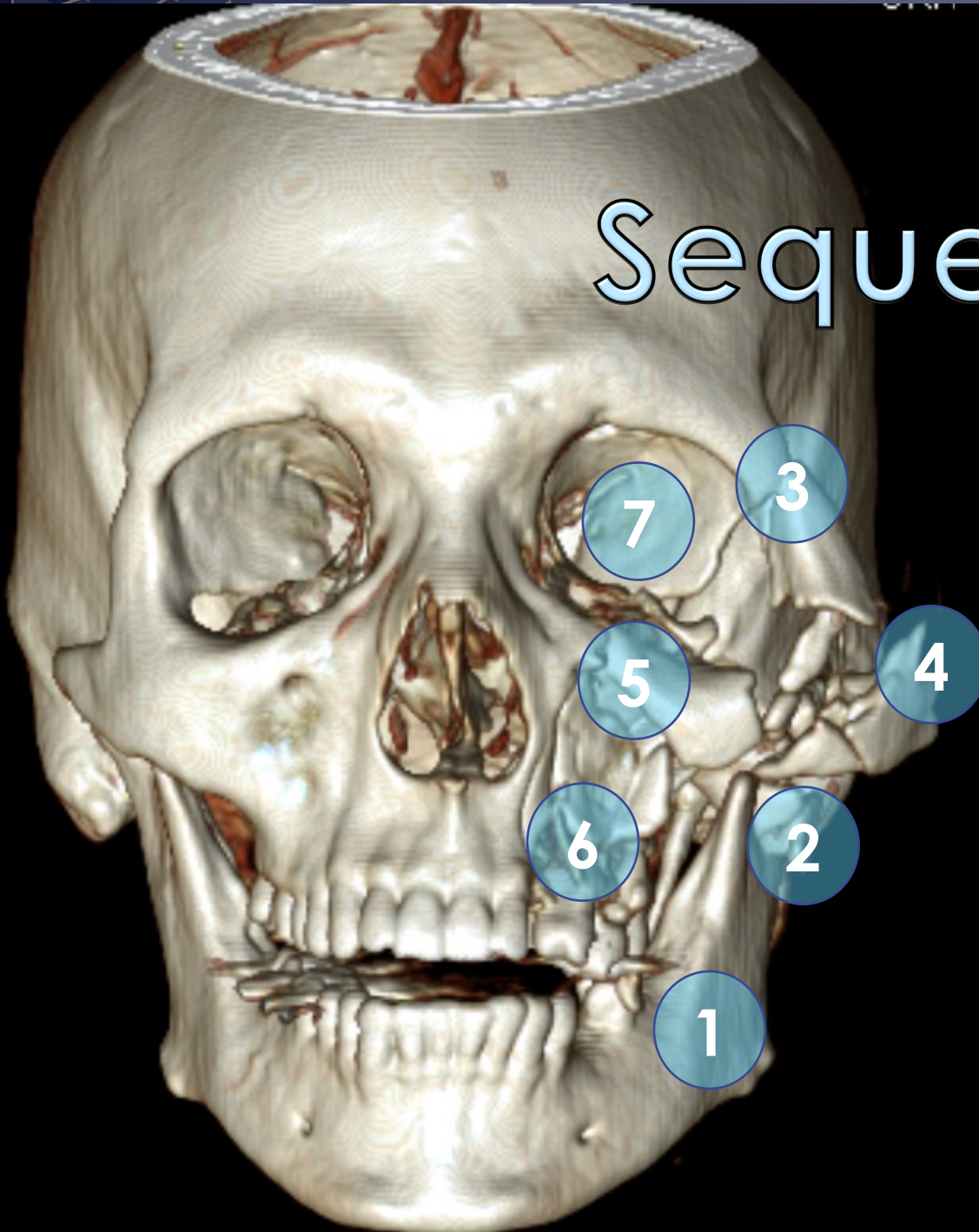




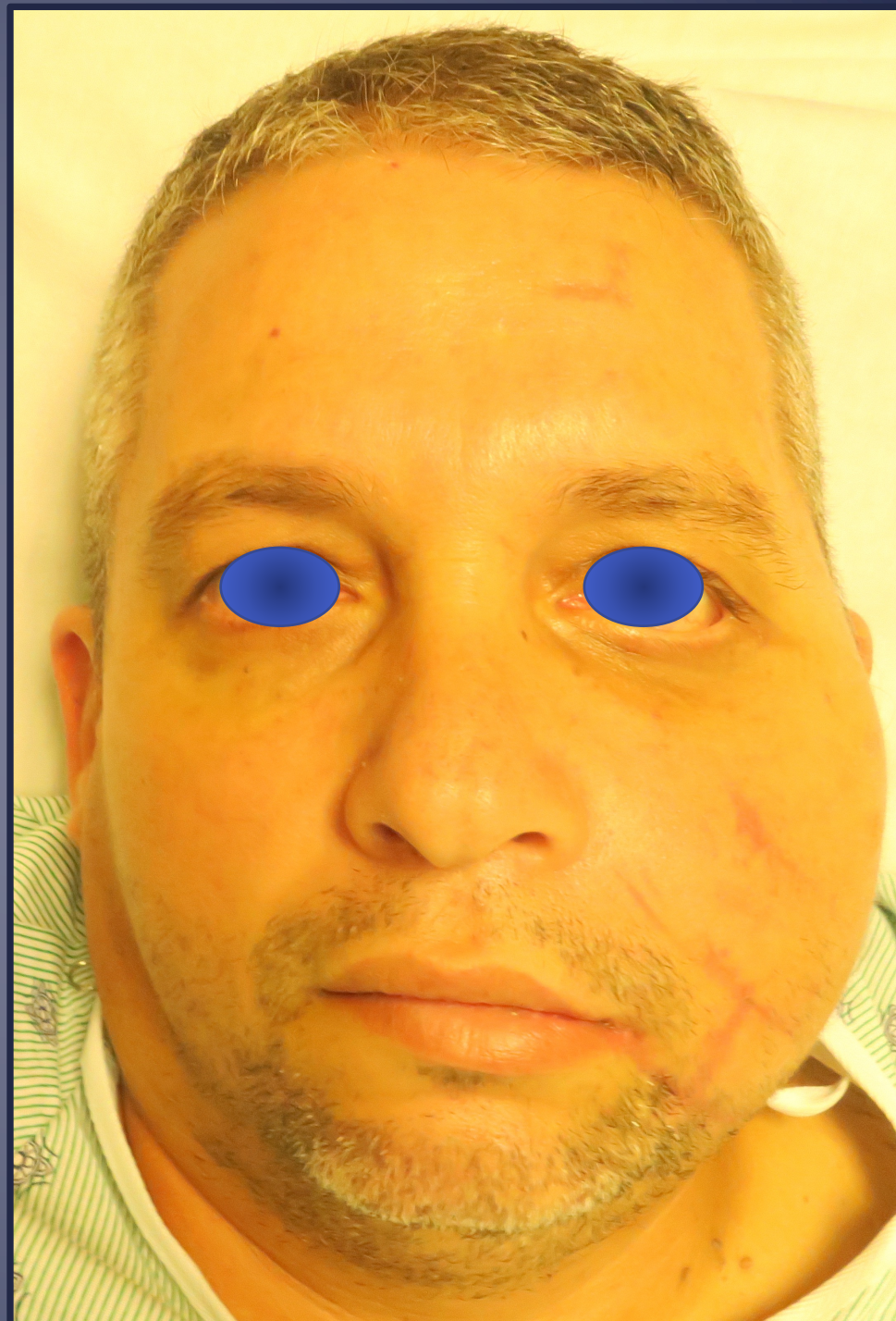Left Subcondylar

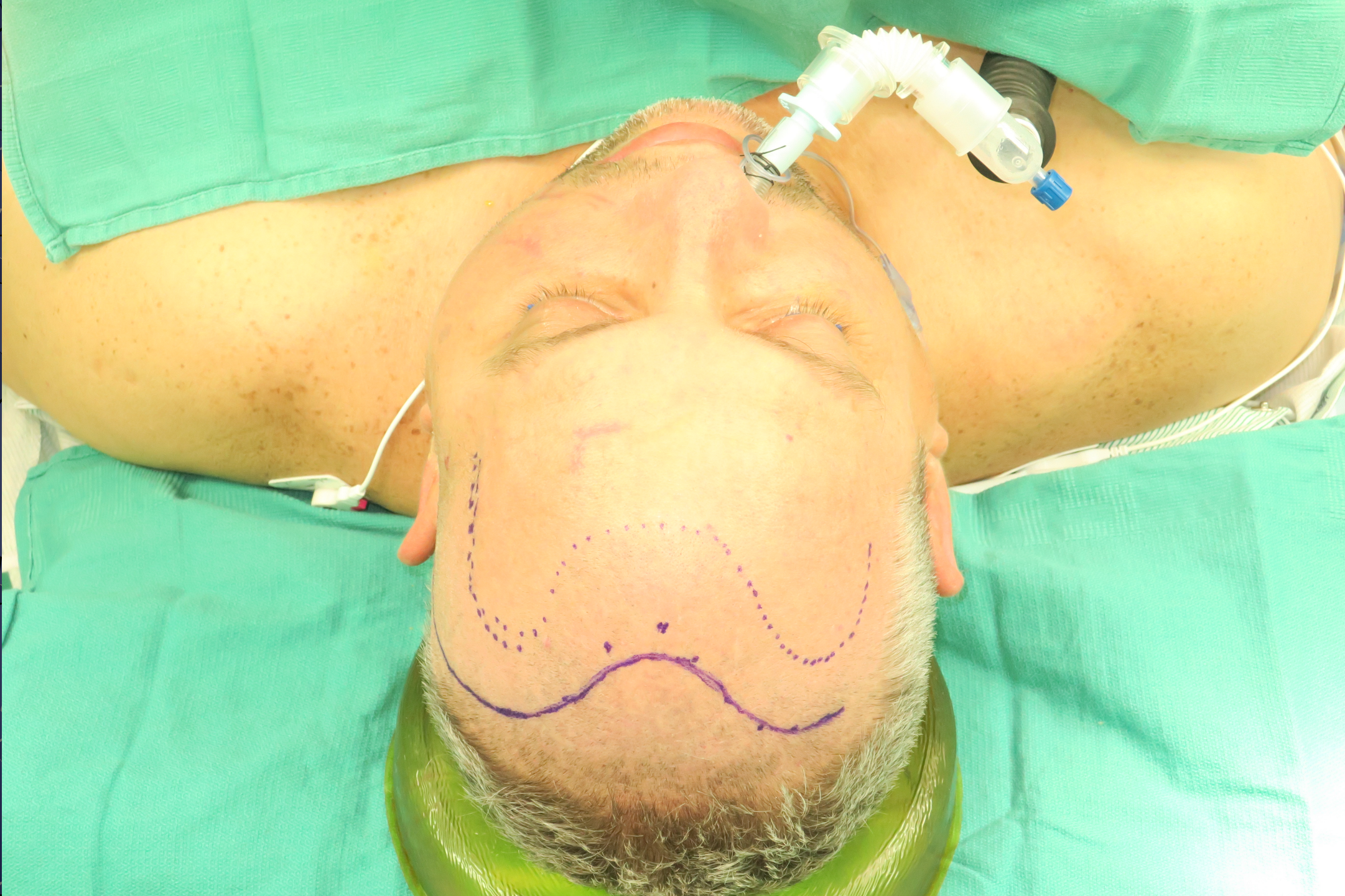

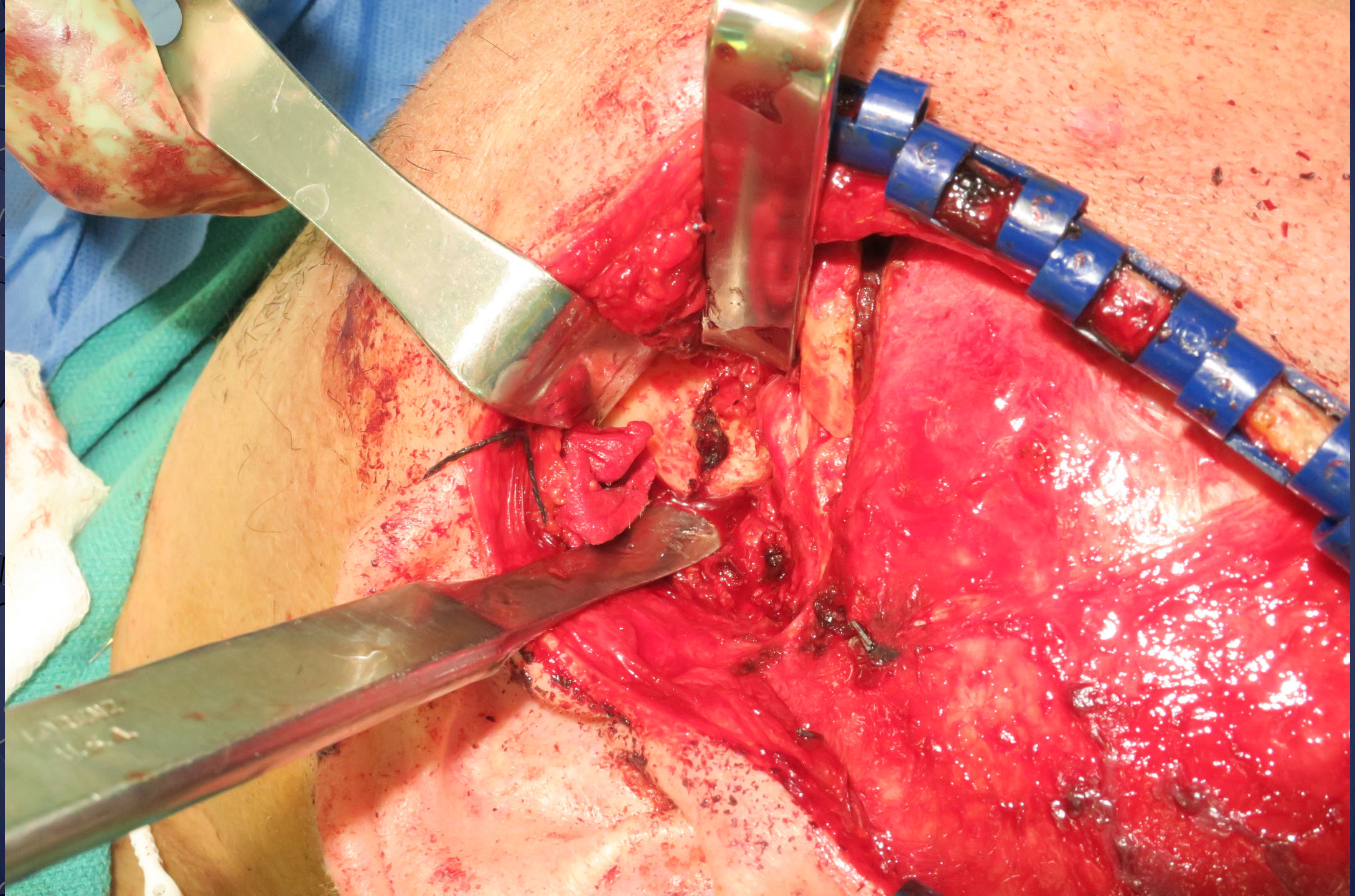
Sequencing

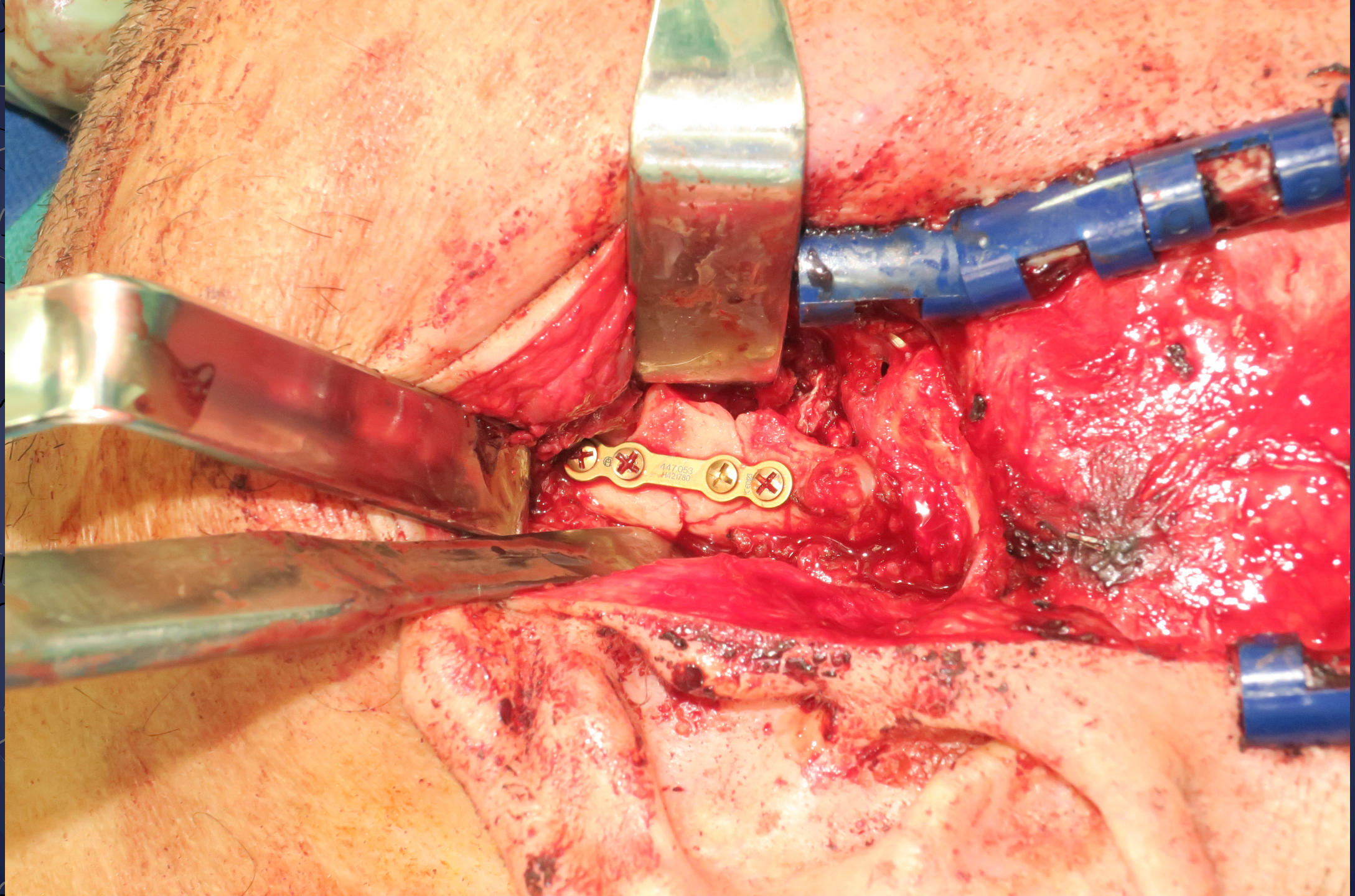


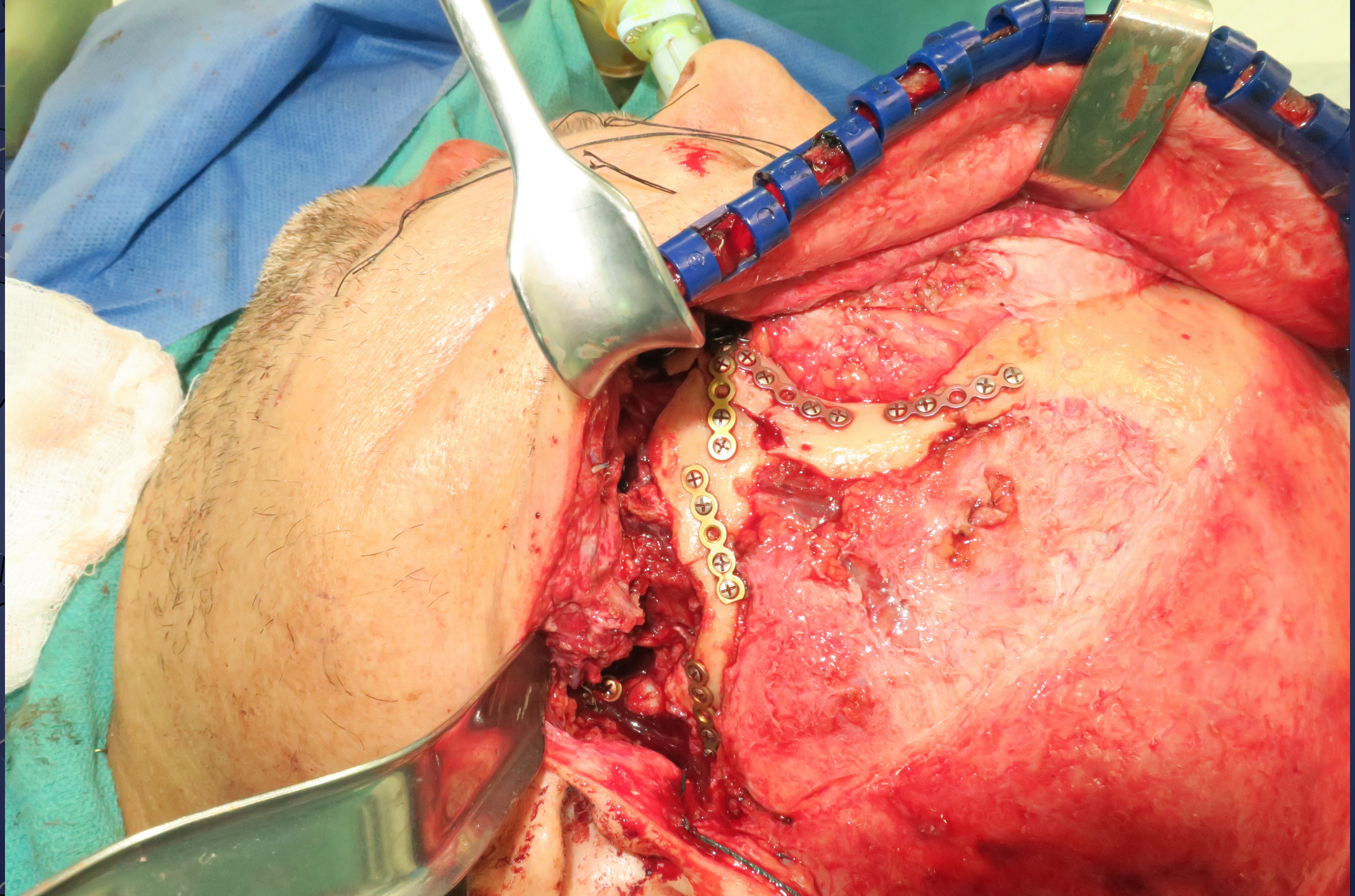
Day of Surgery

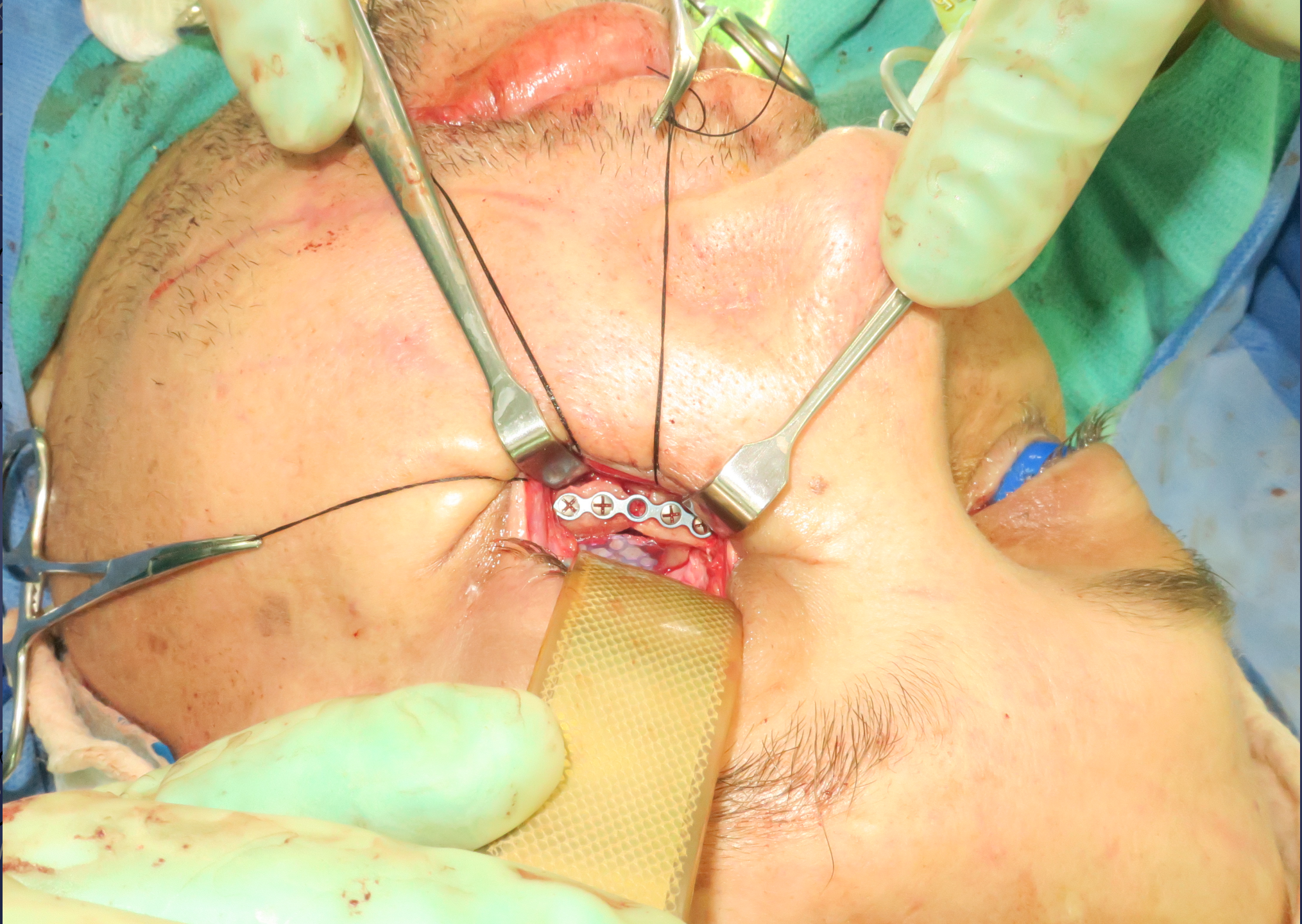


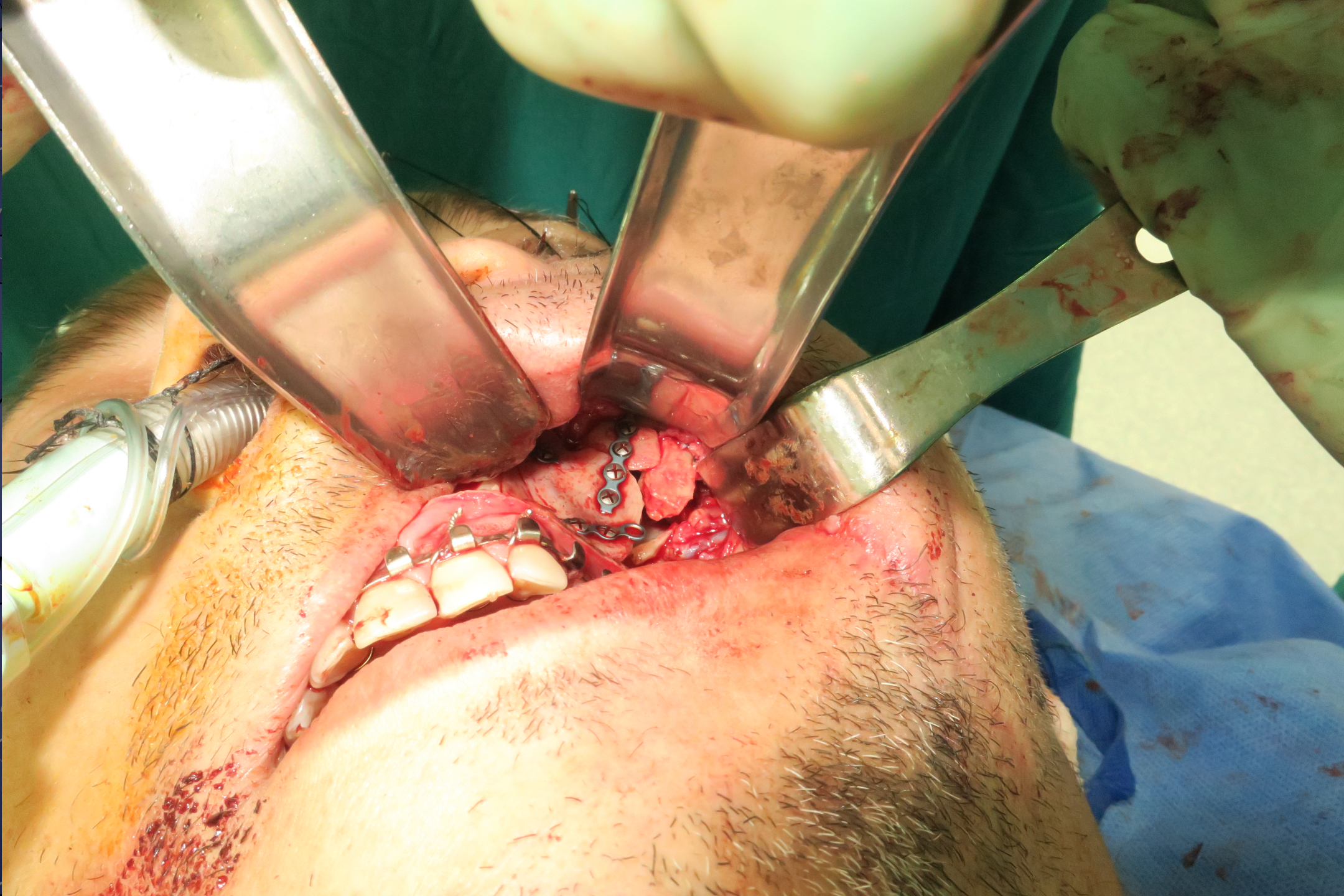


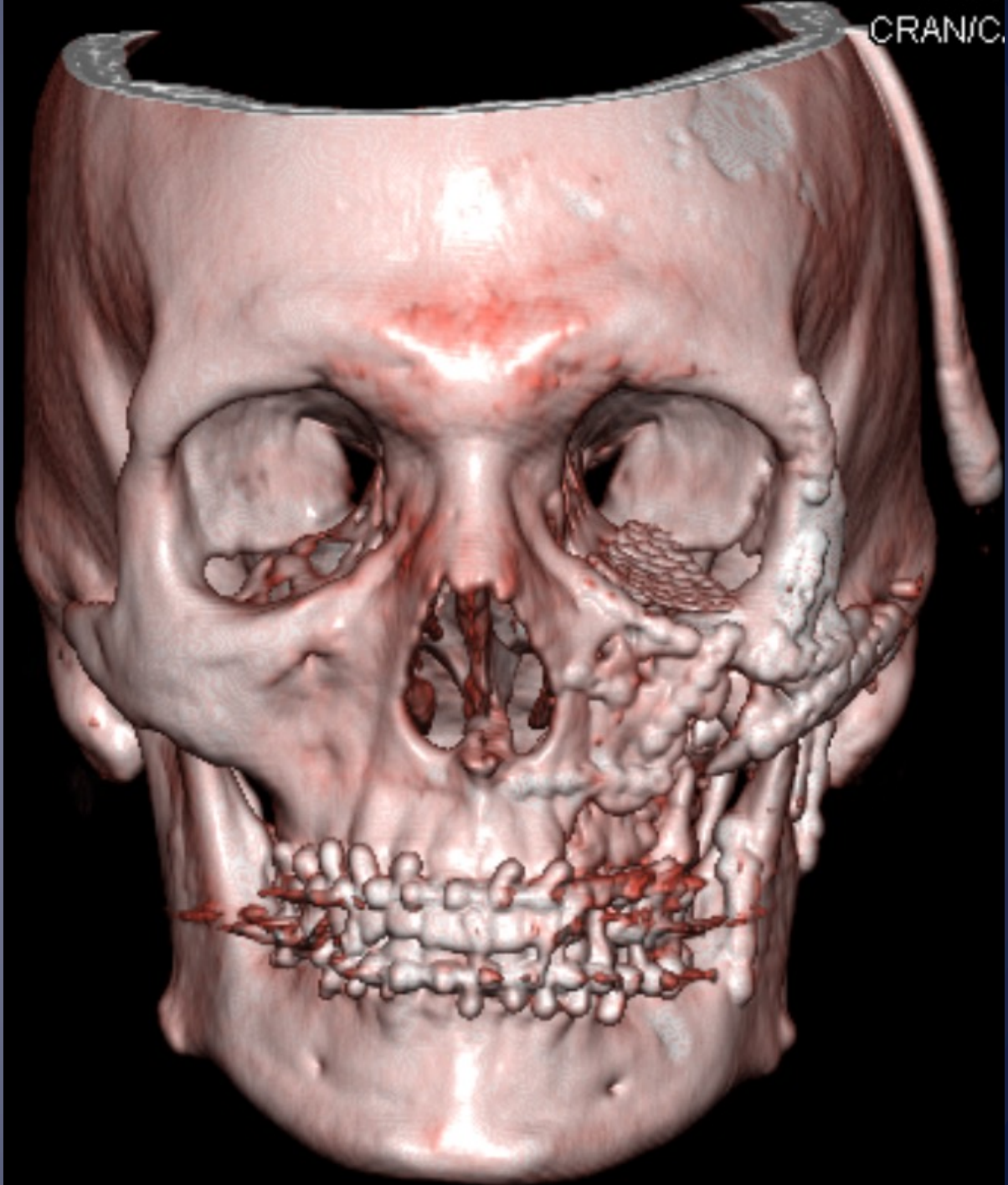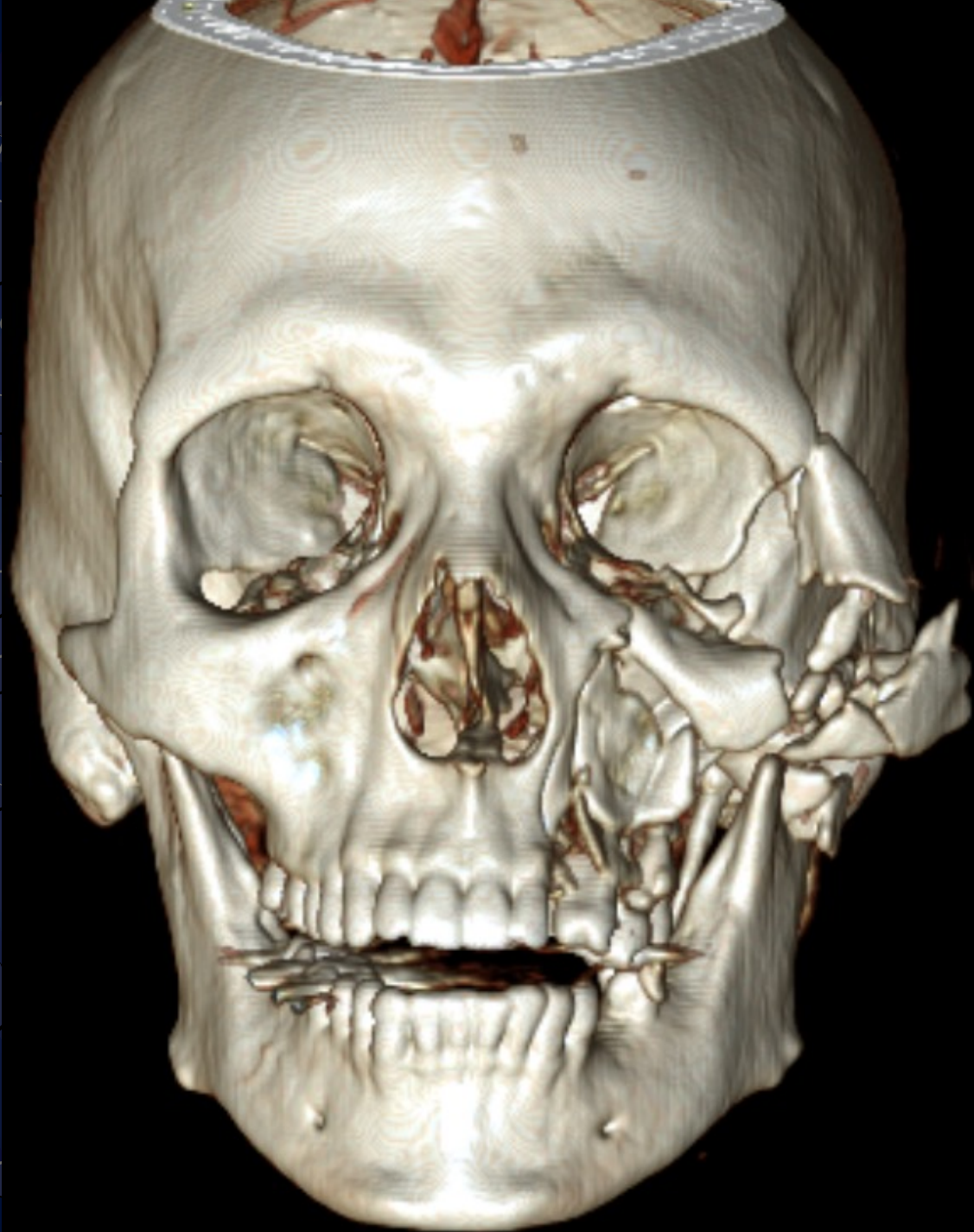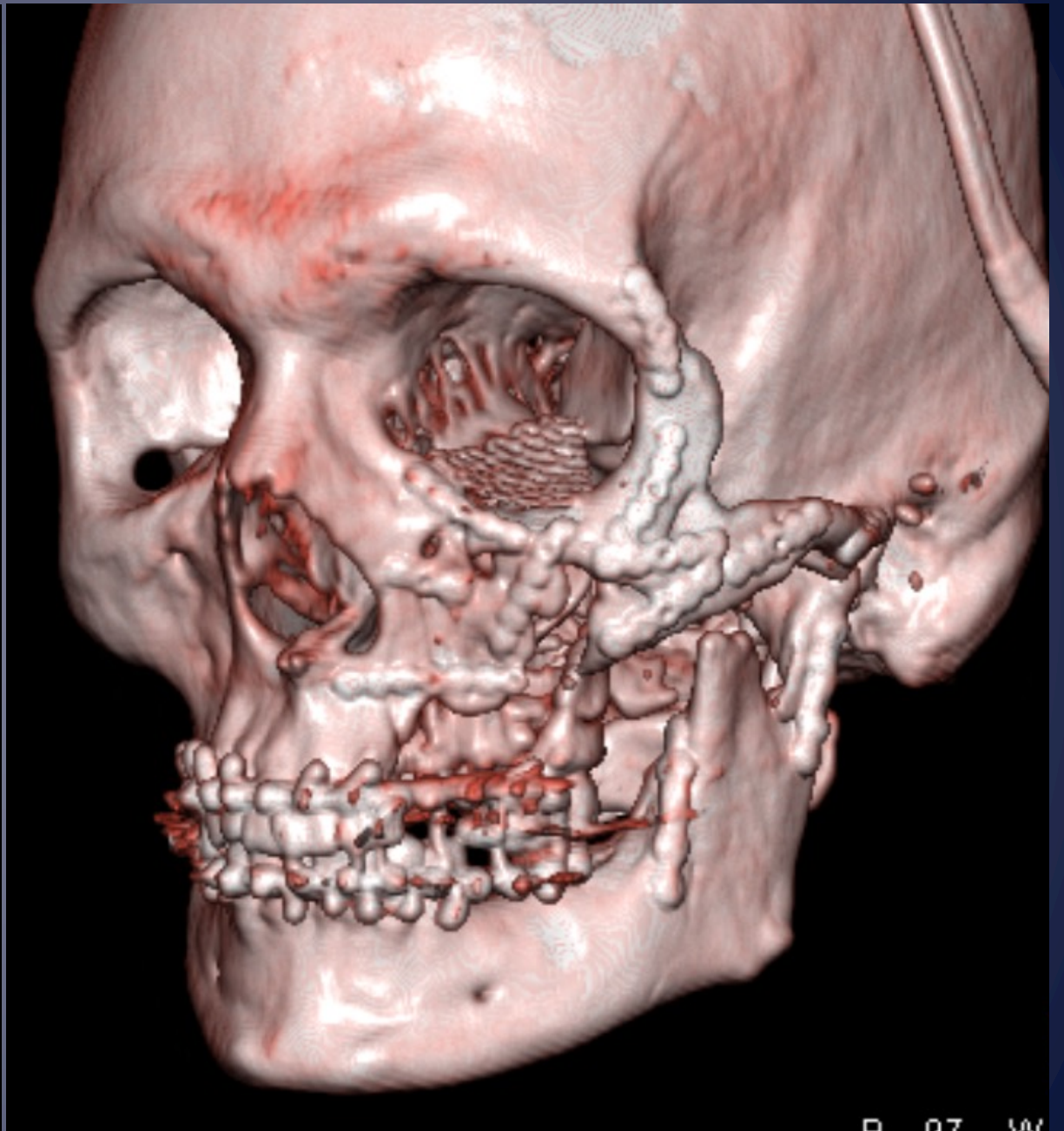




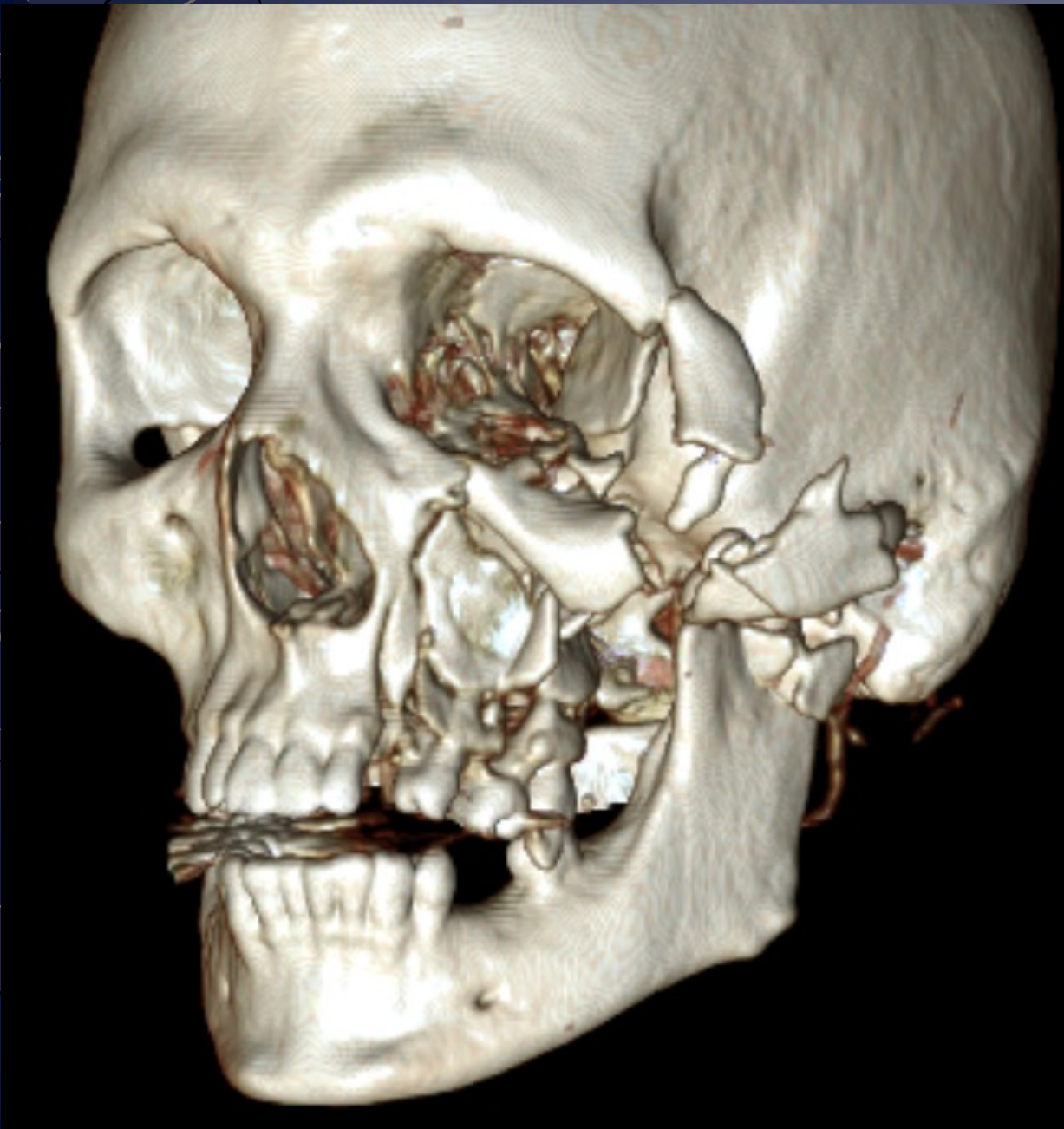


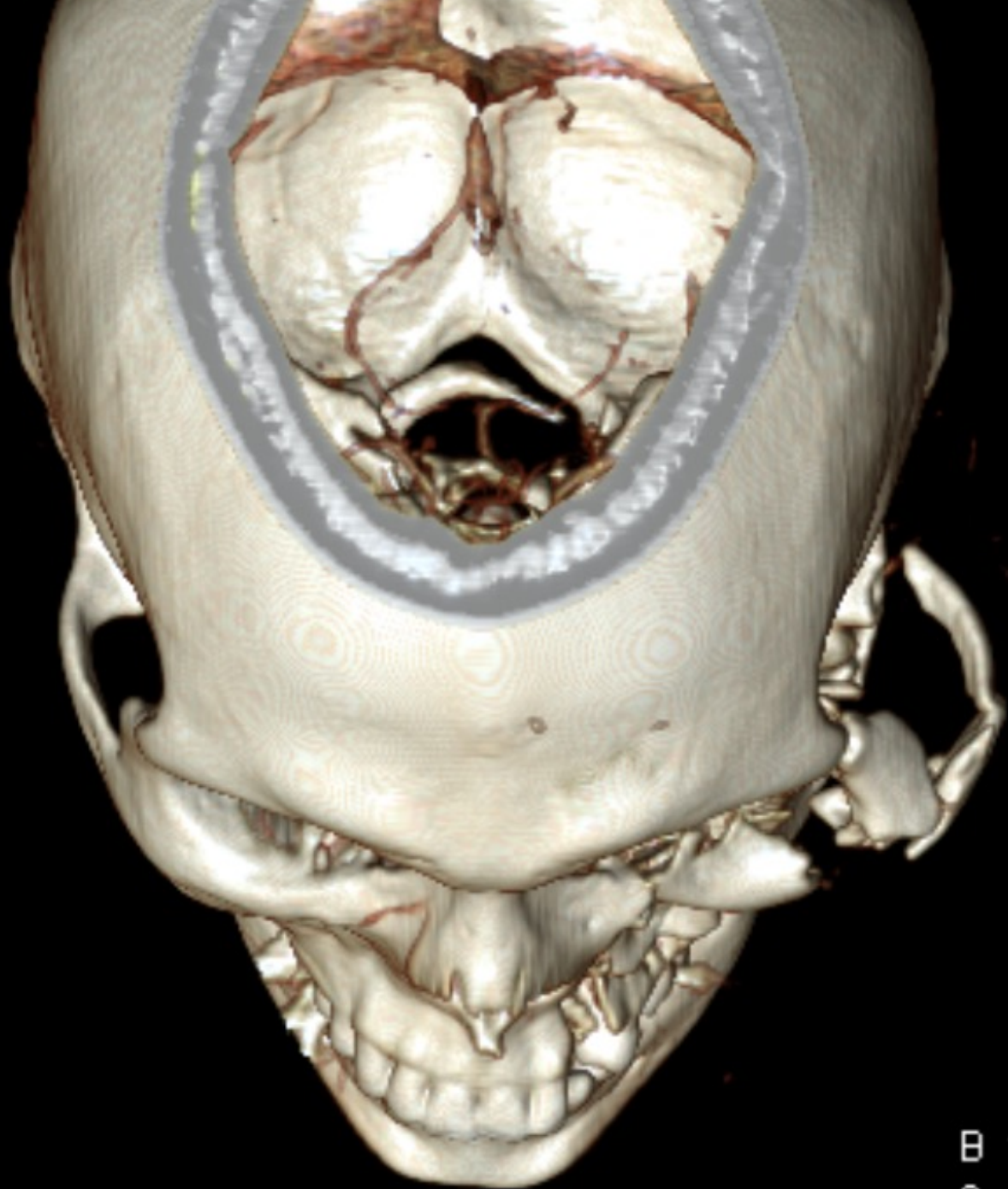


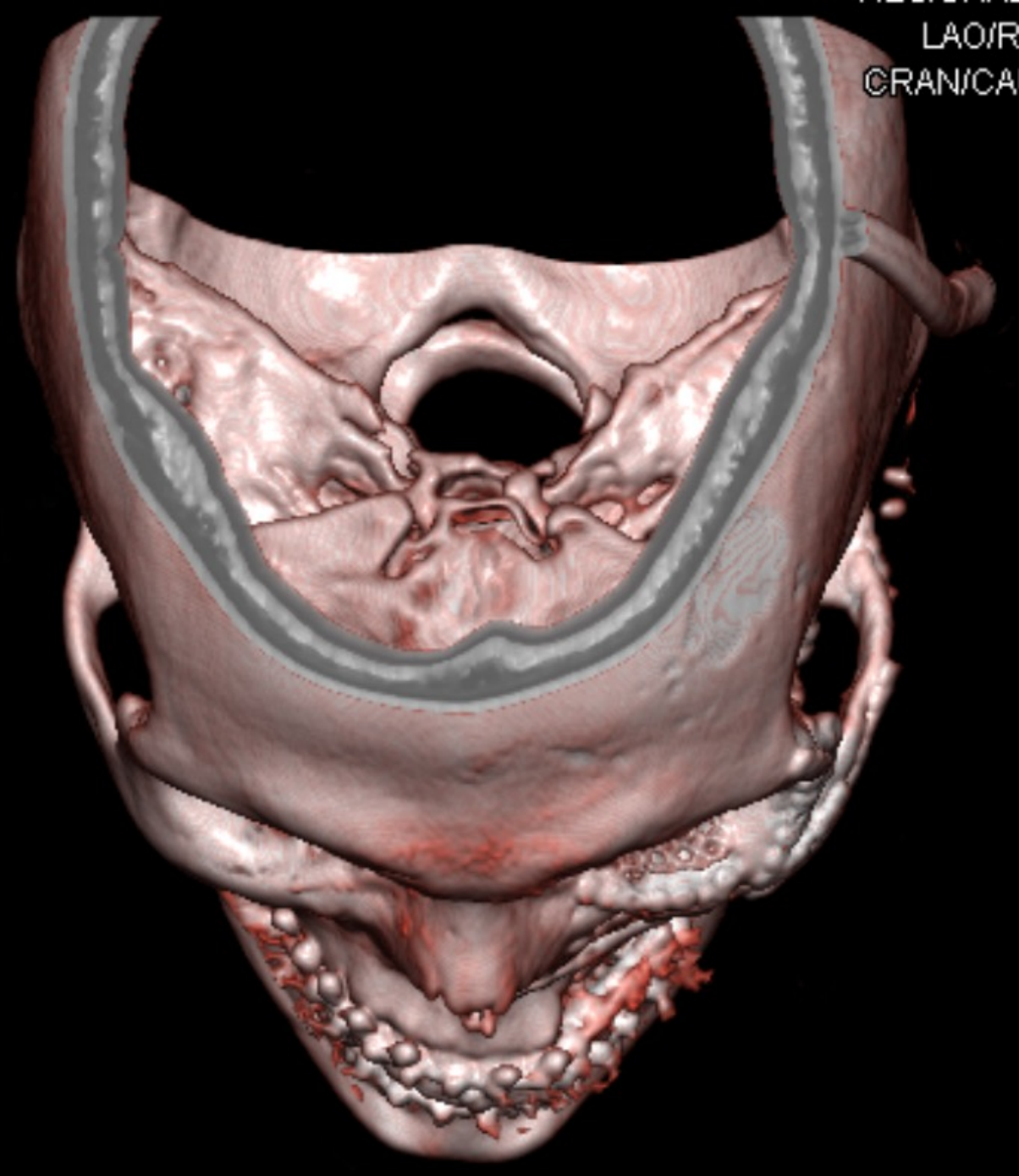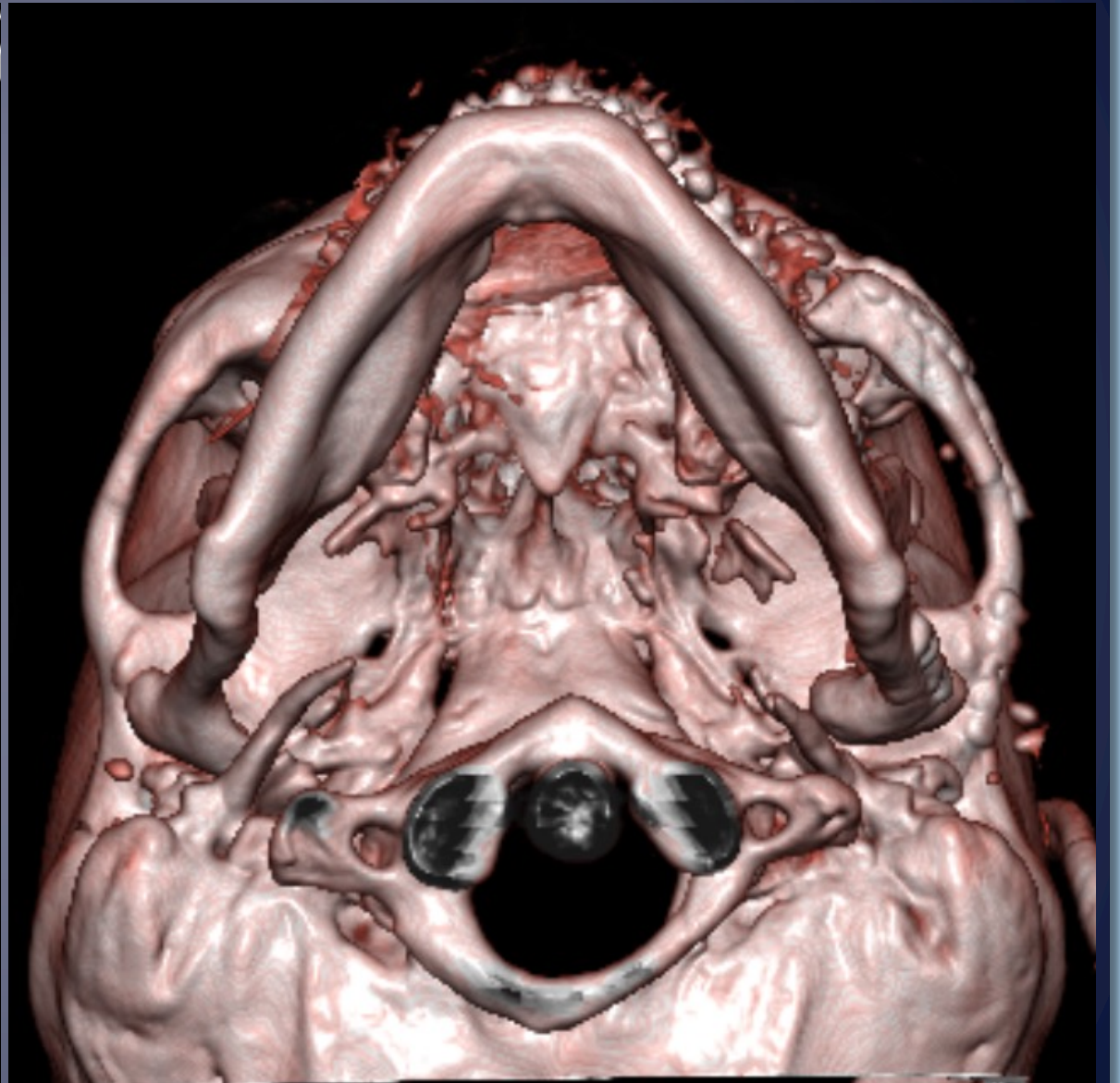


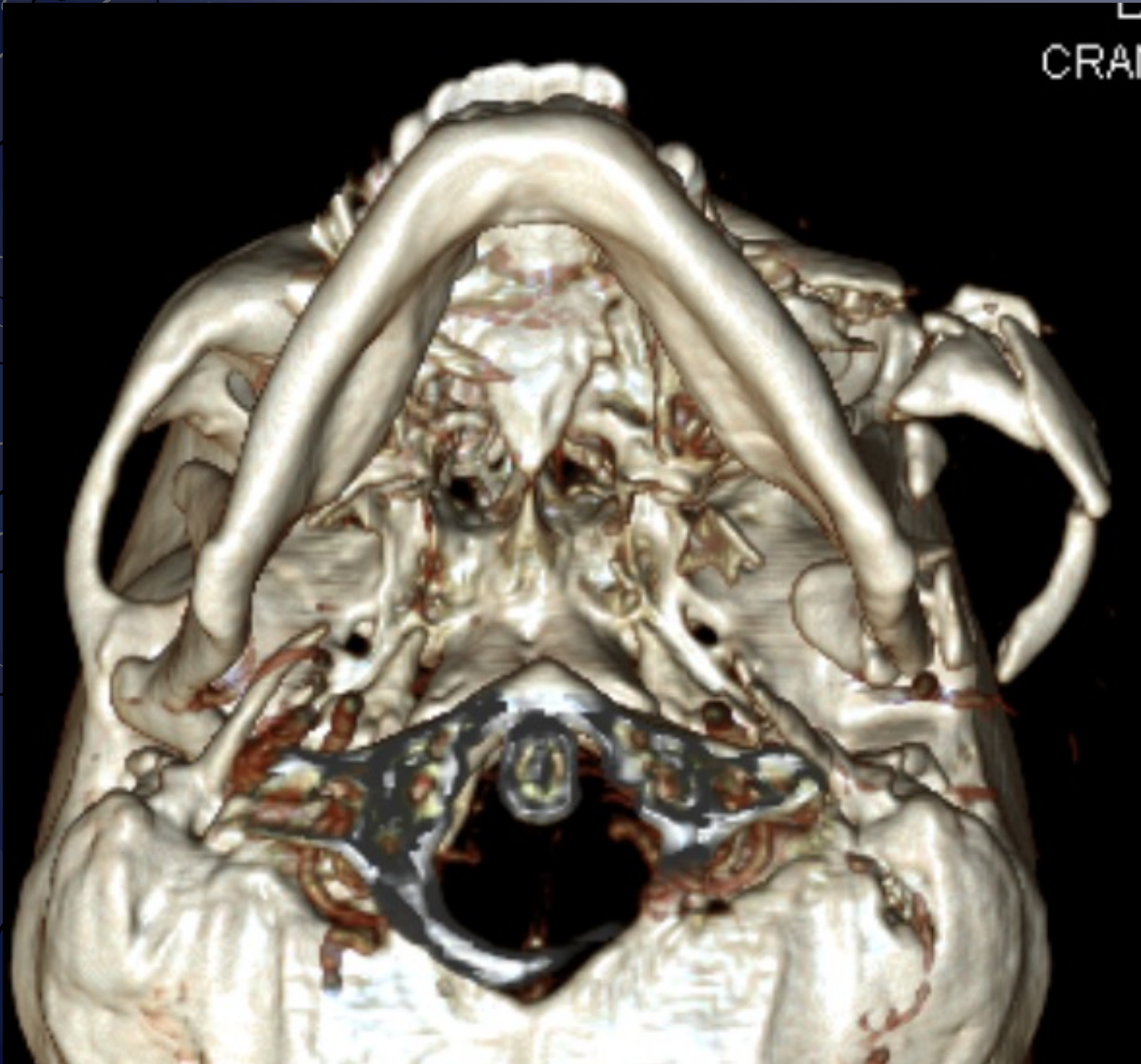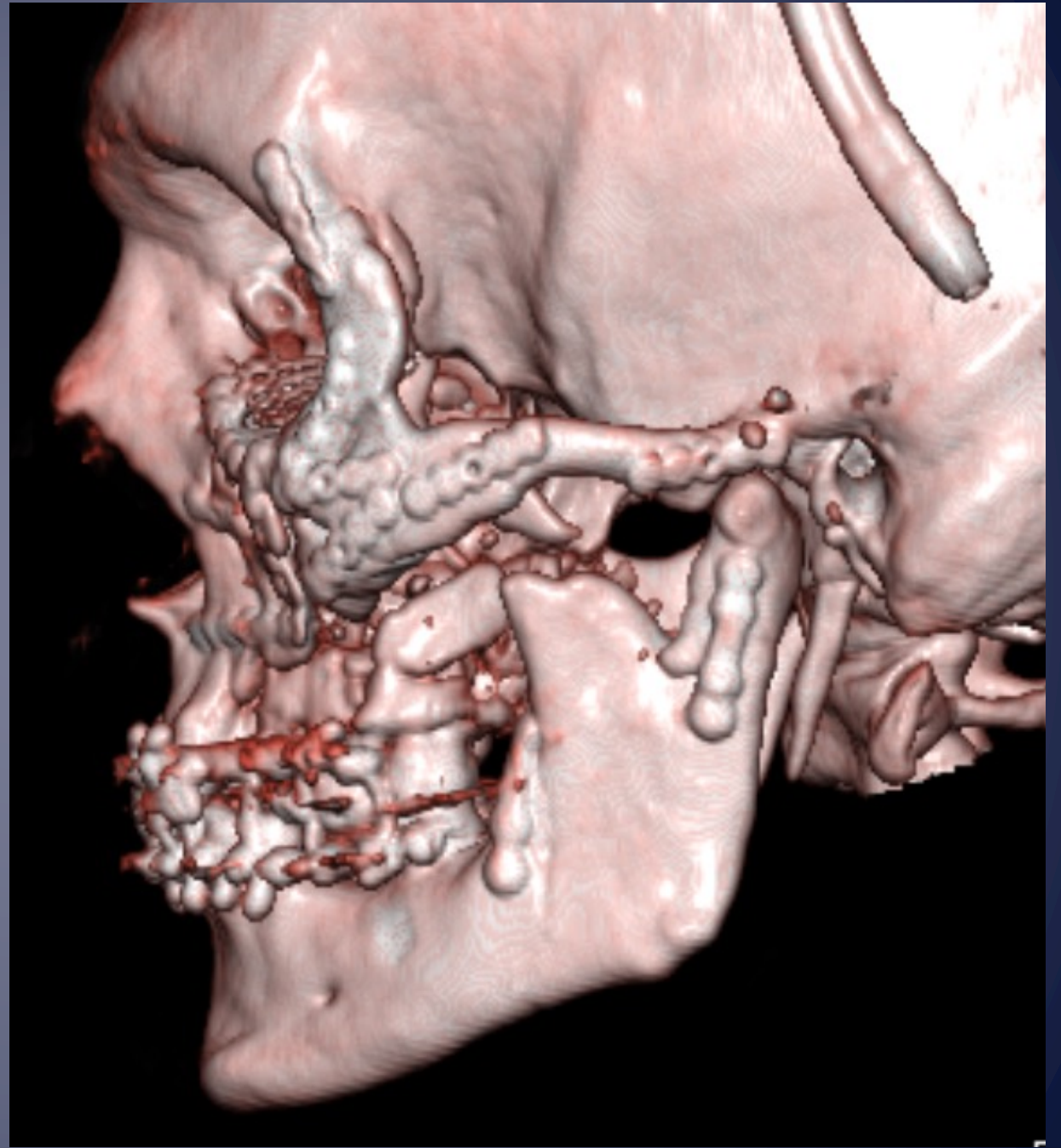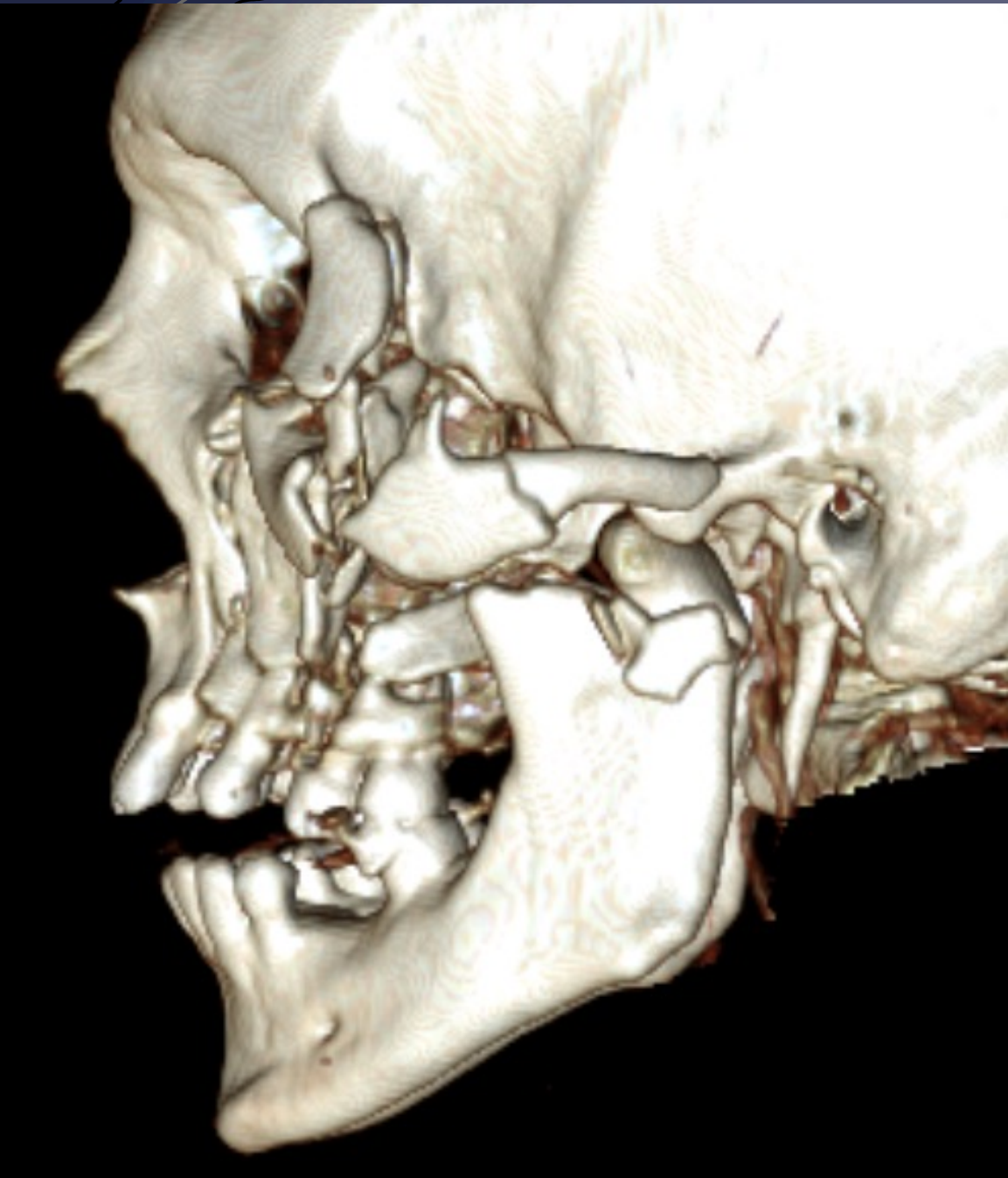


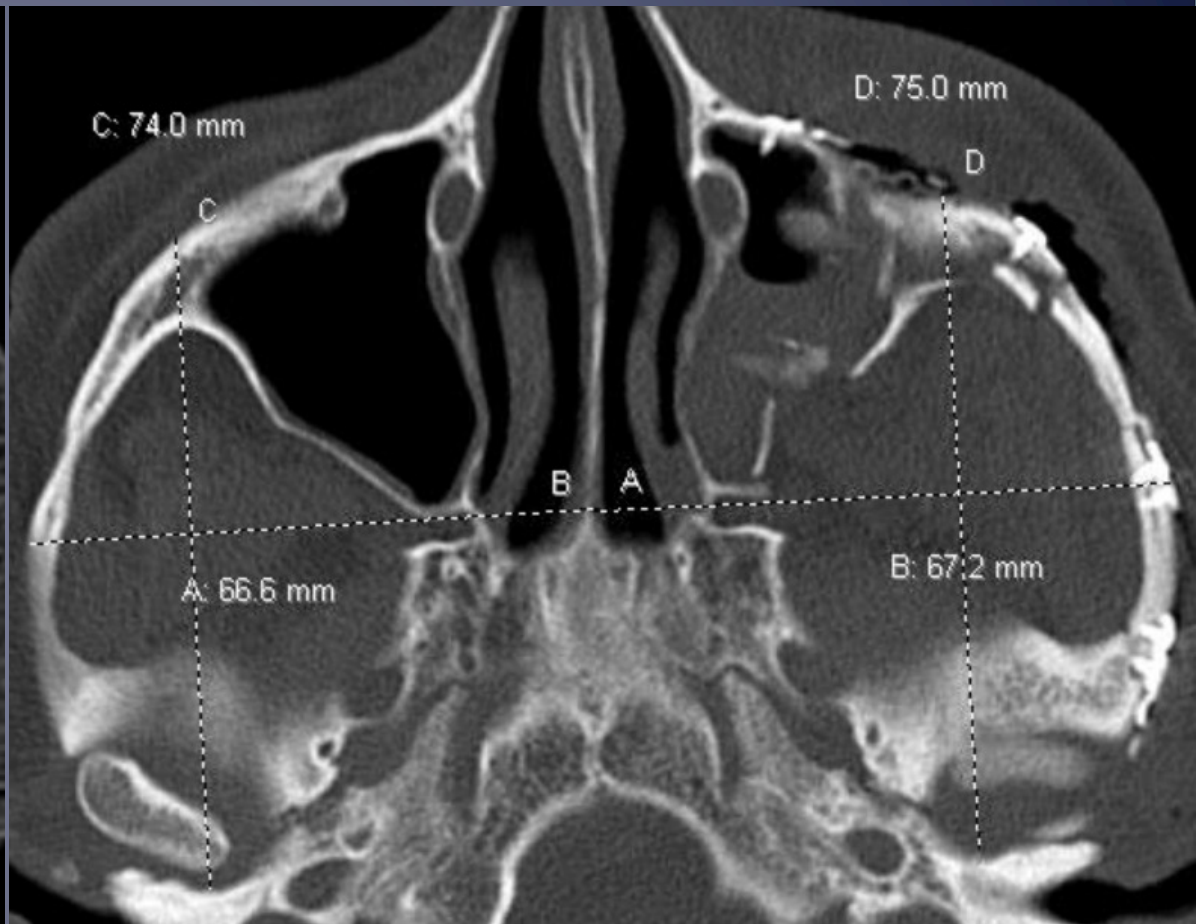
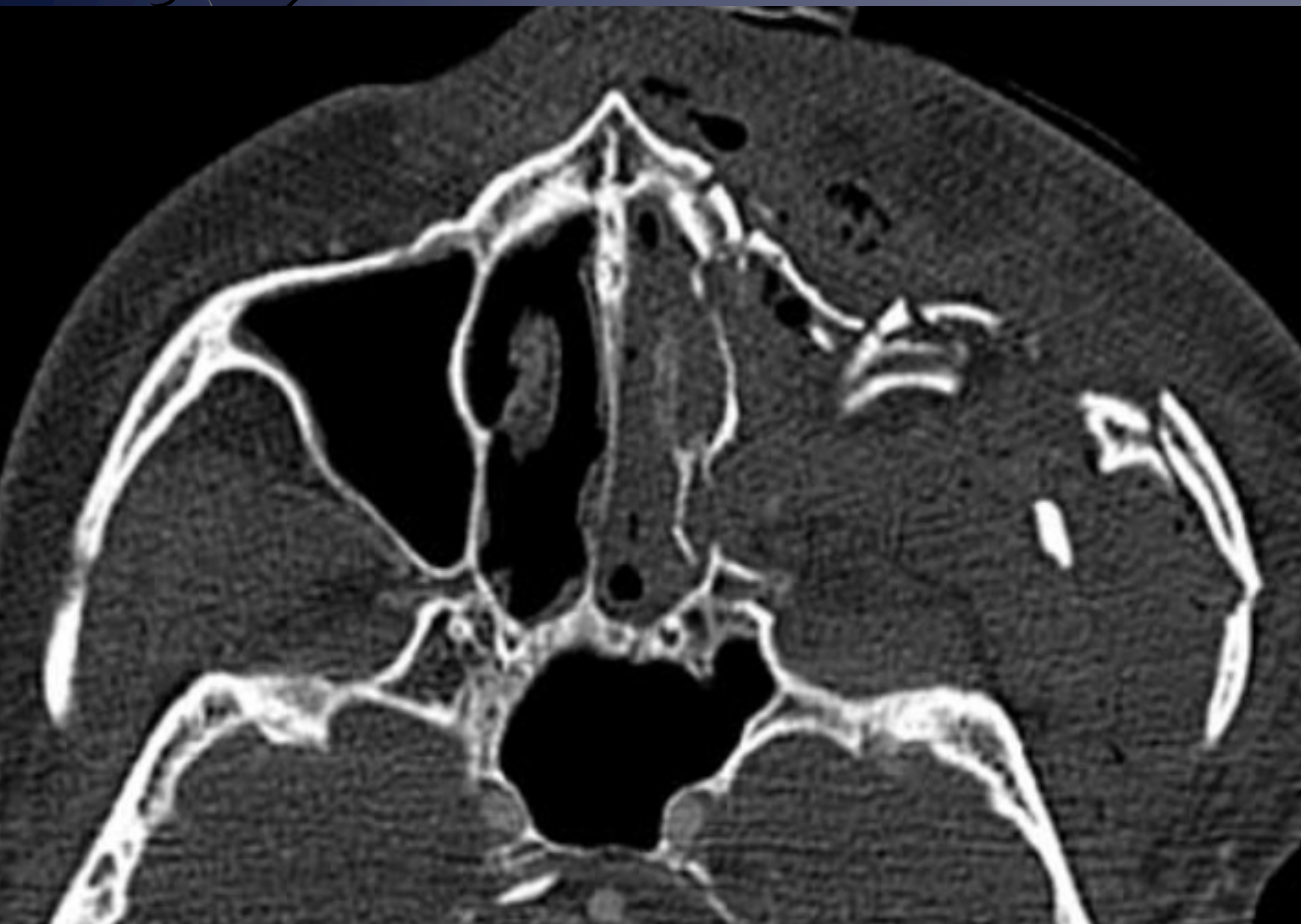O B

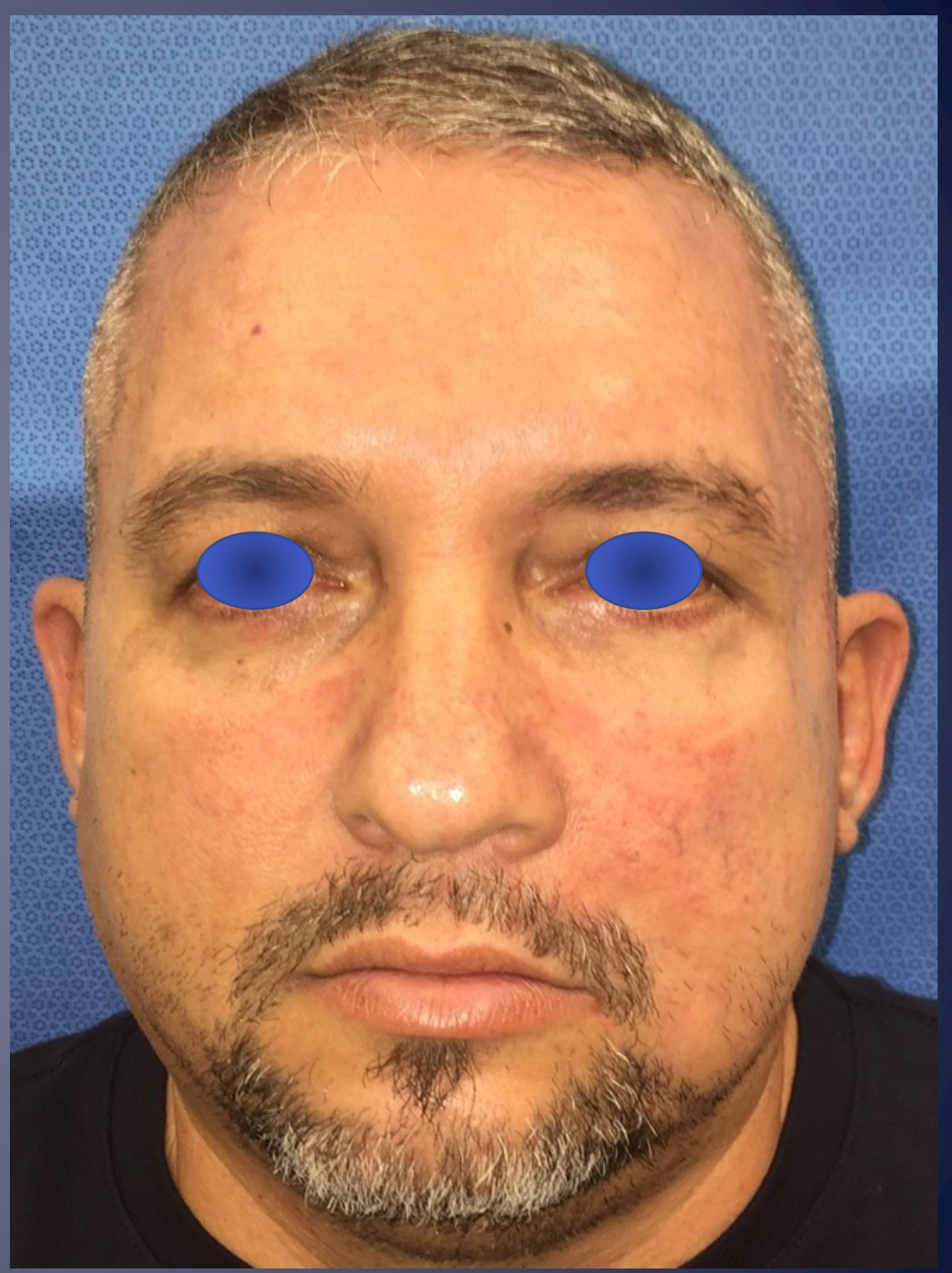
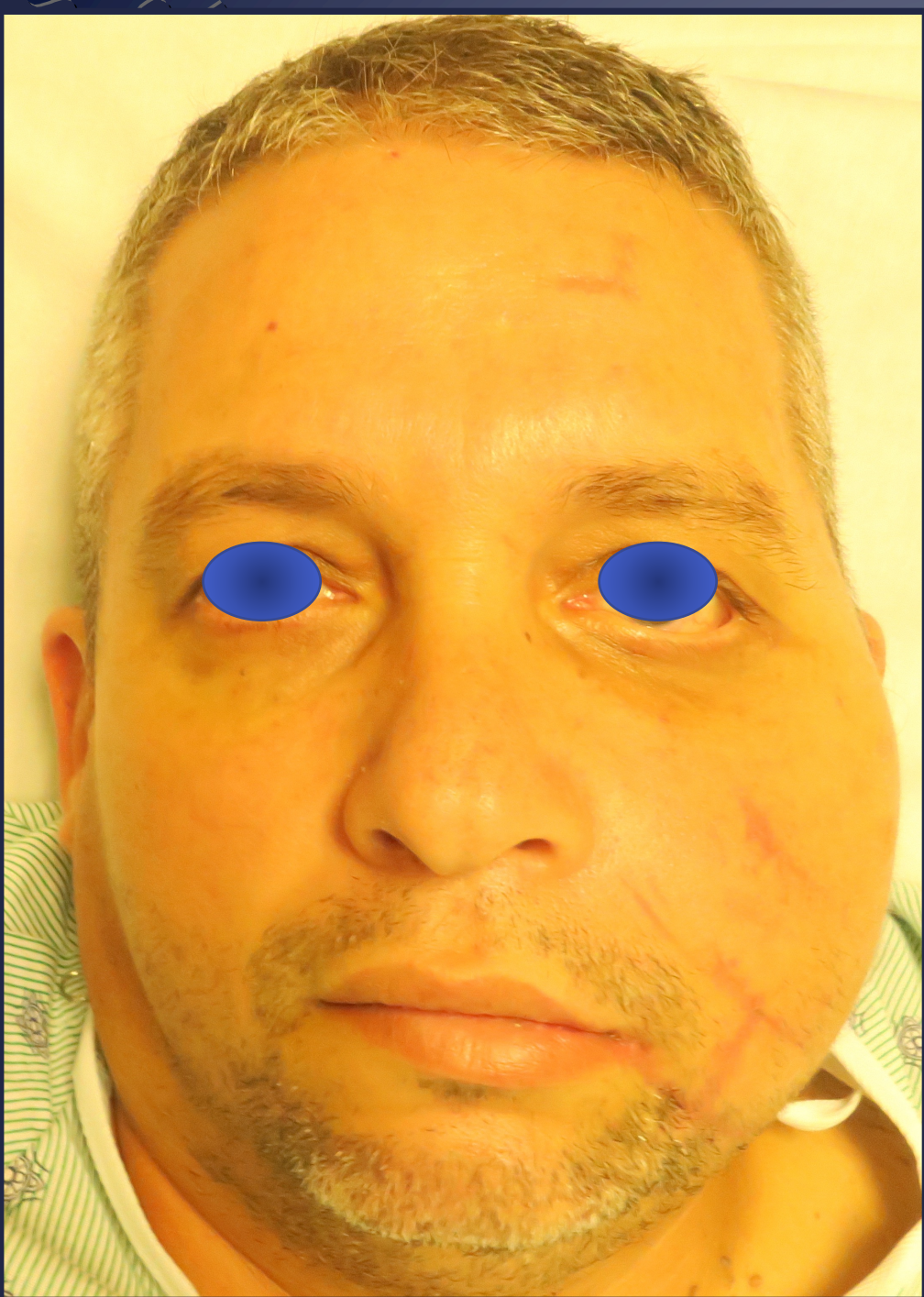

LAO/R
©CRAN/CA









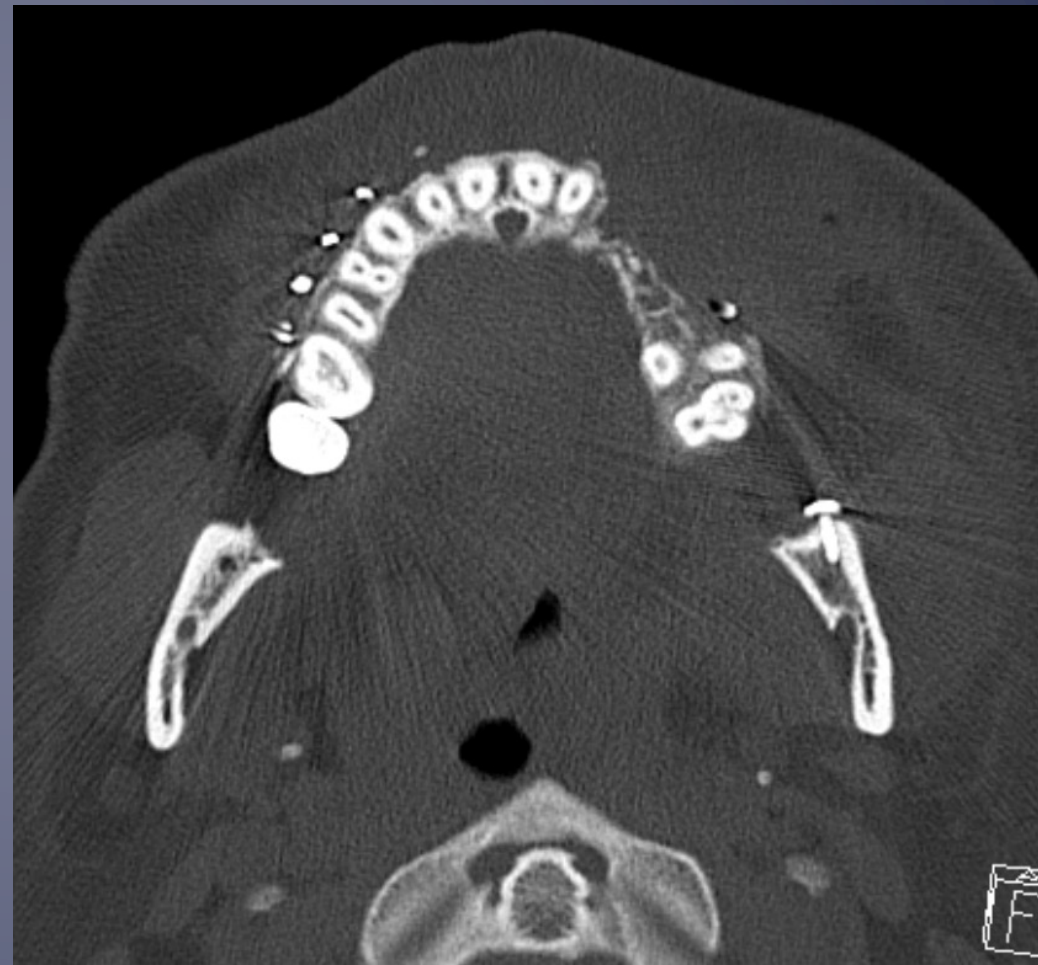
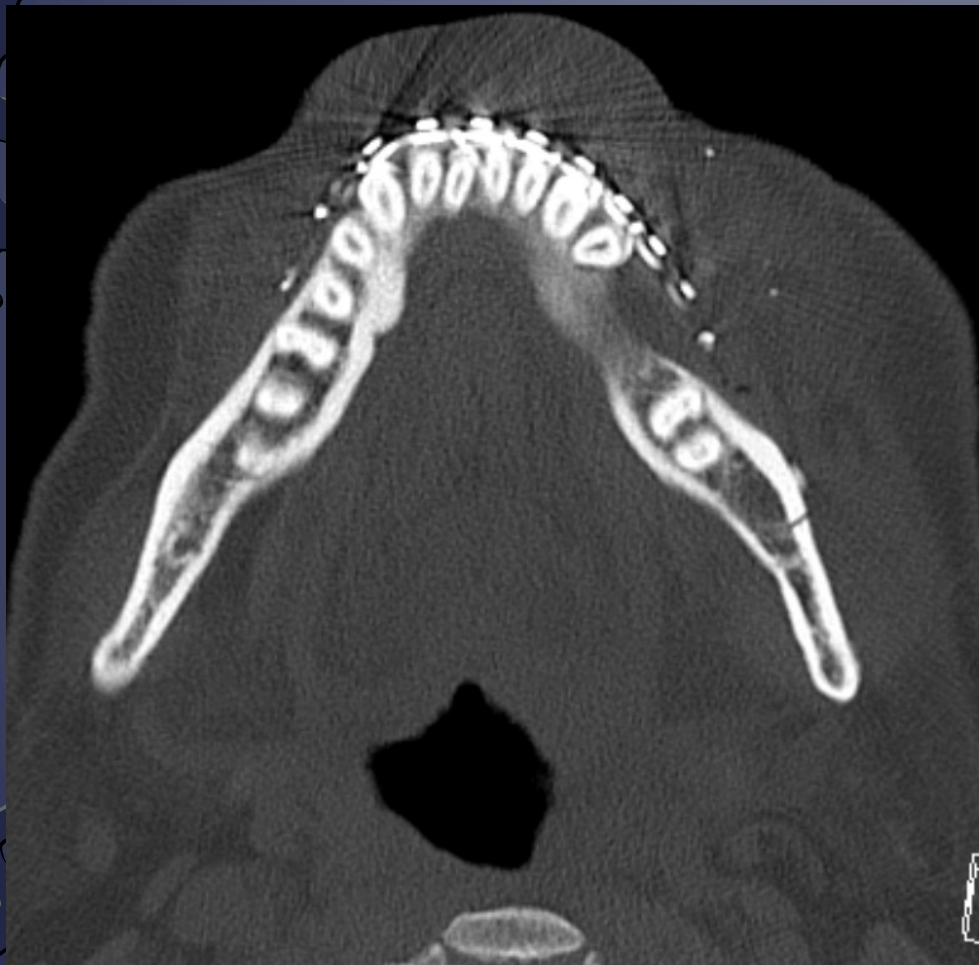
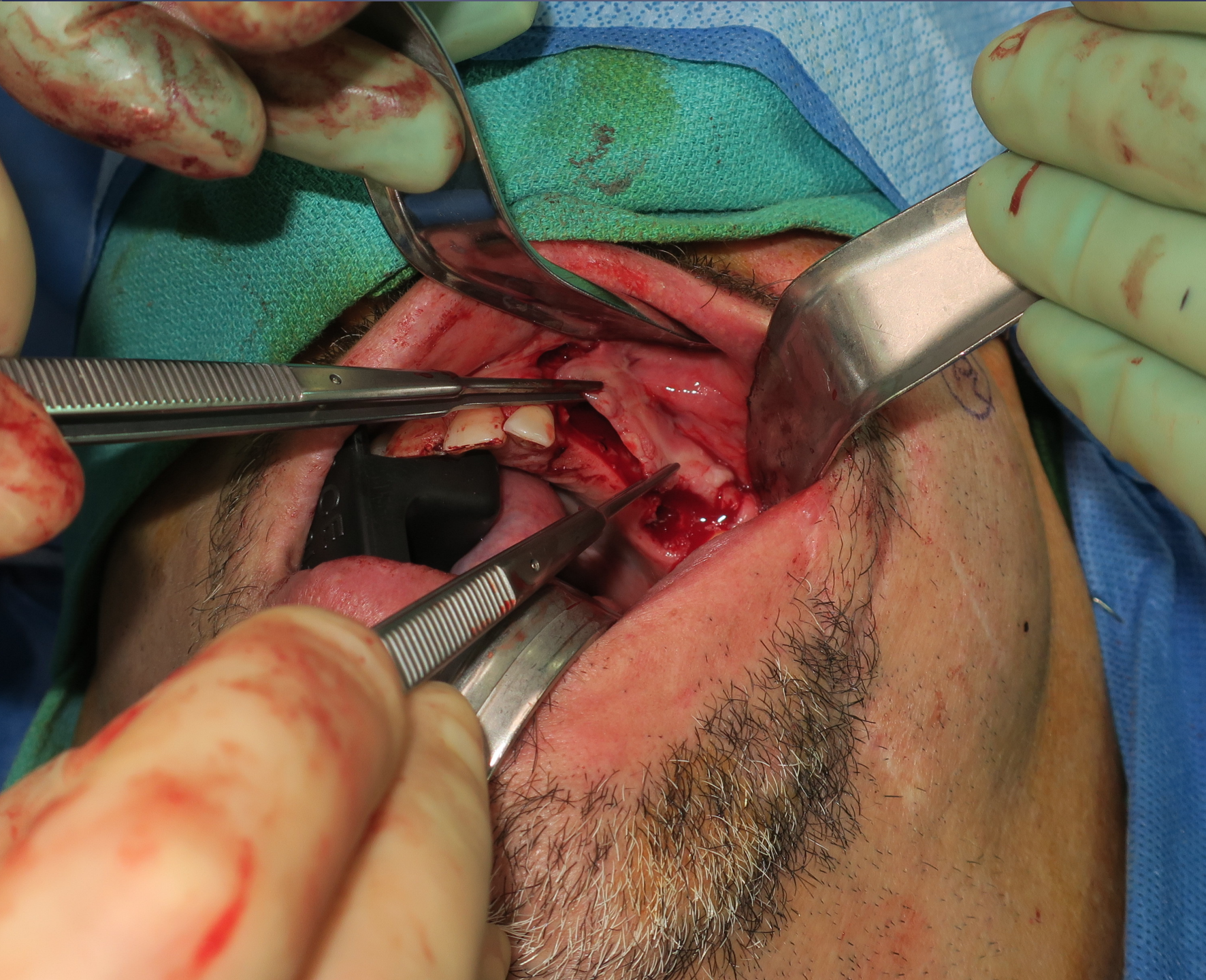
PHASE II

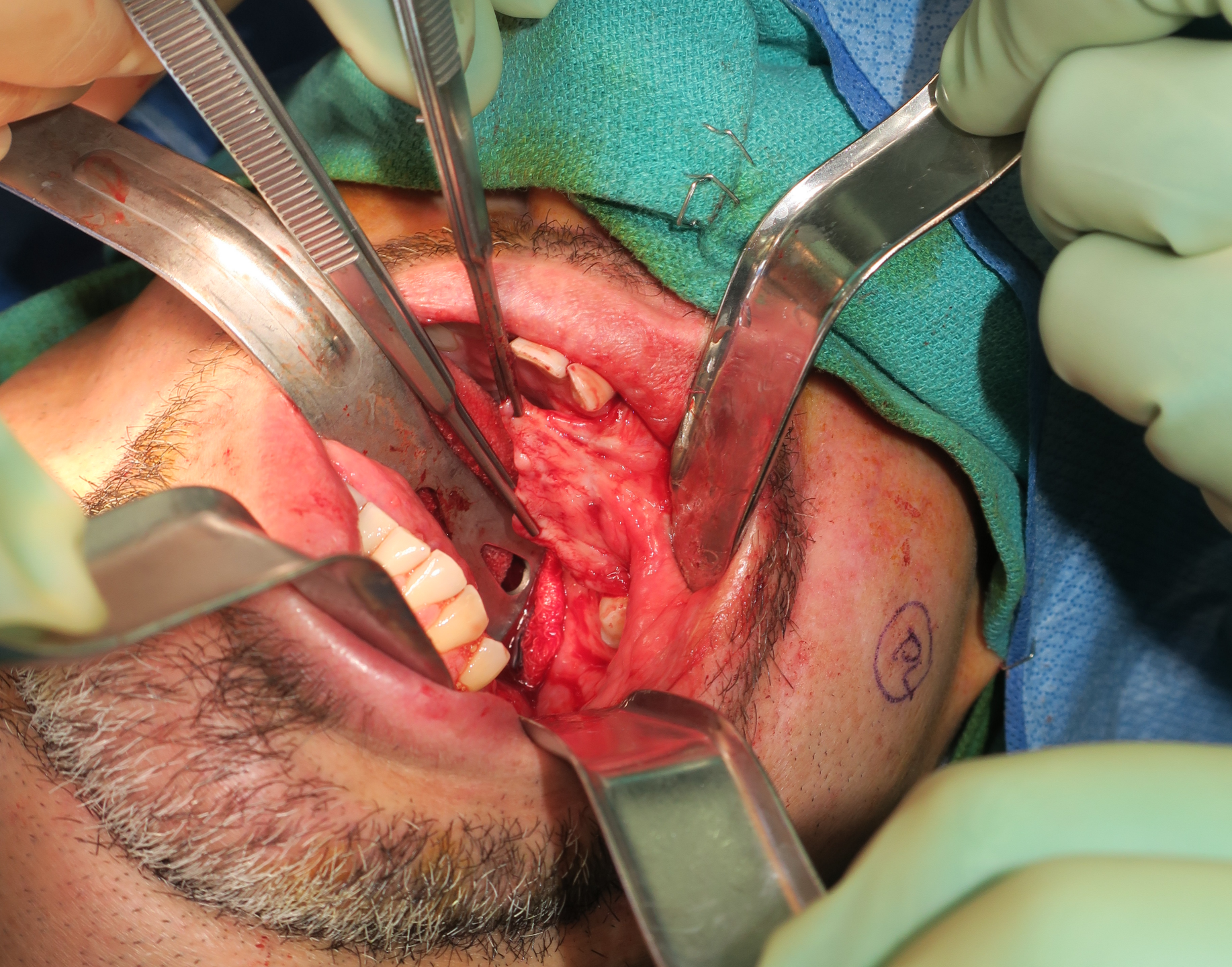


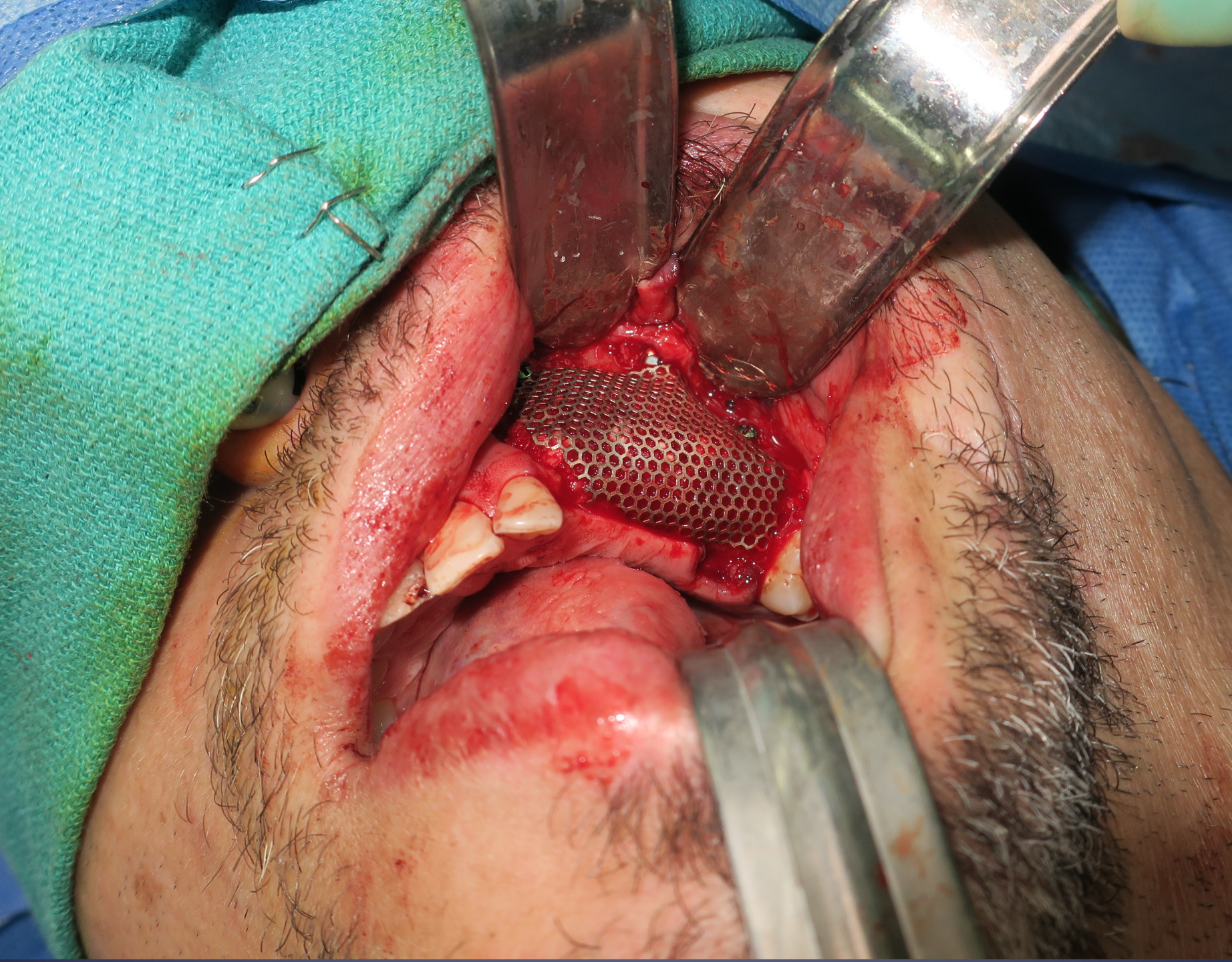Dentoalveolar Reconstruction

Dentoalveolar Reconstruction

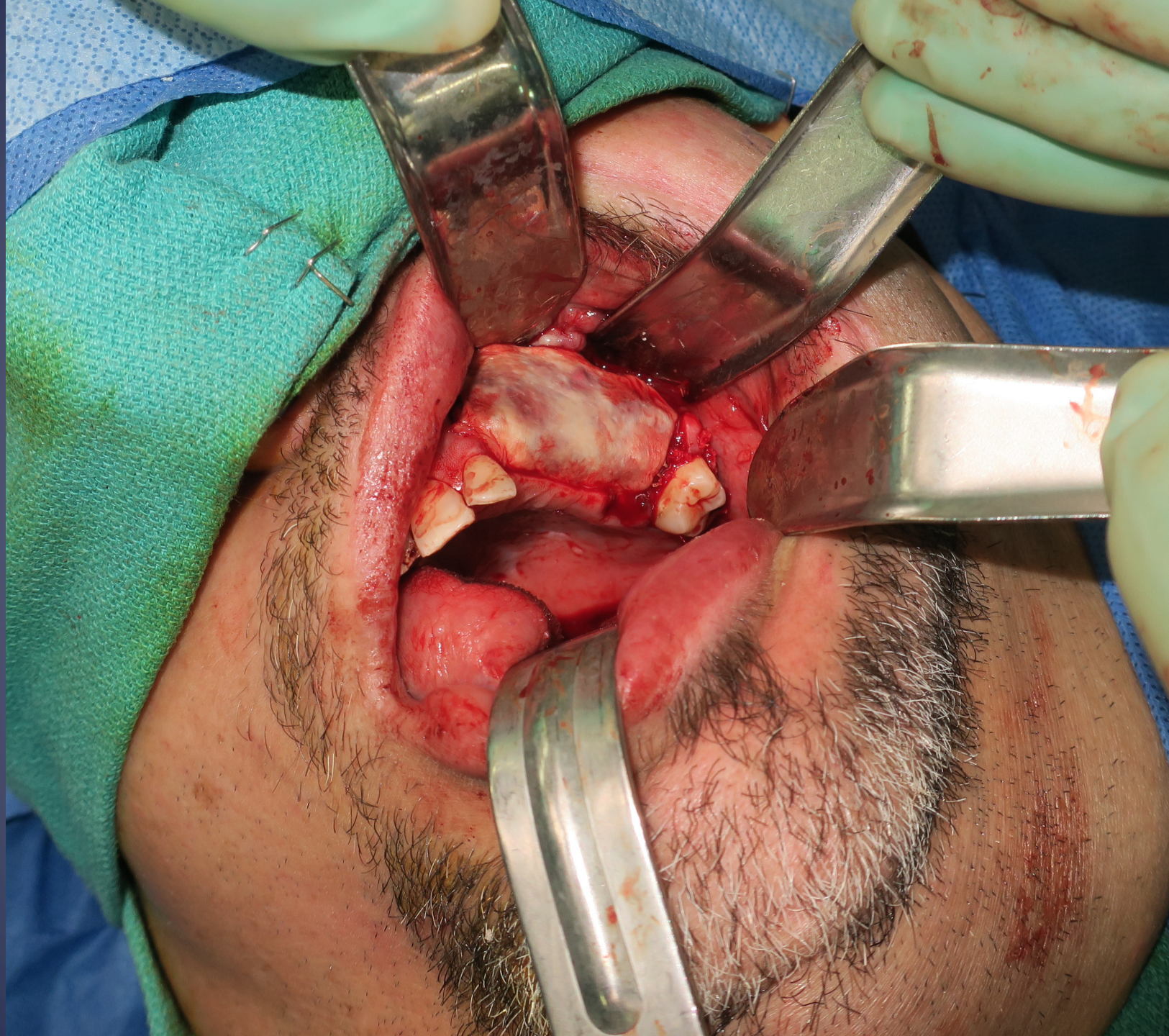




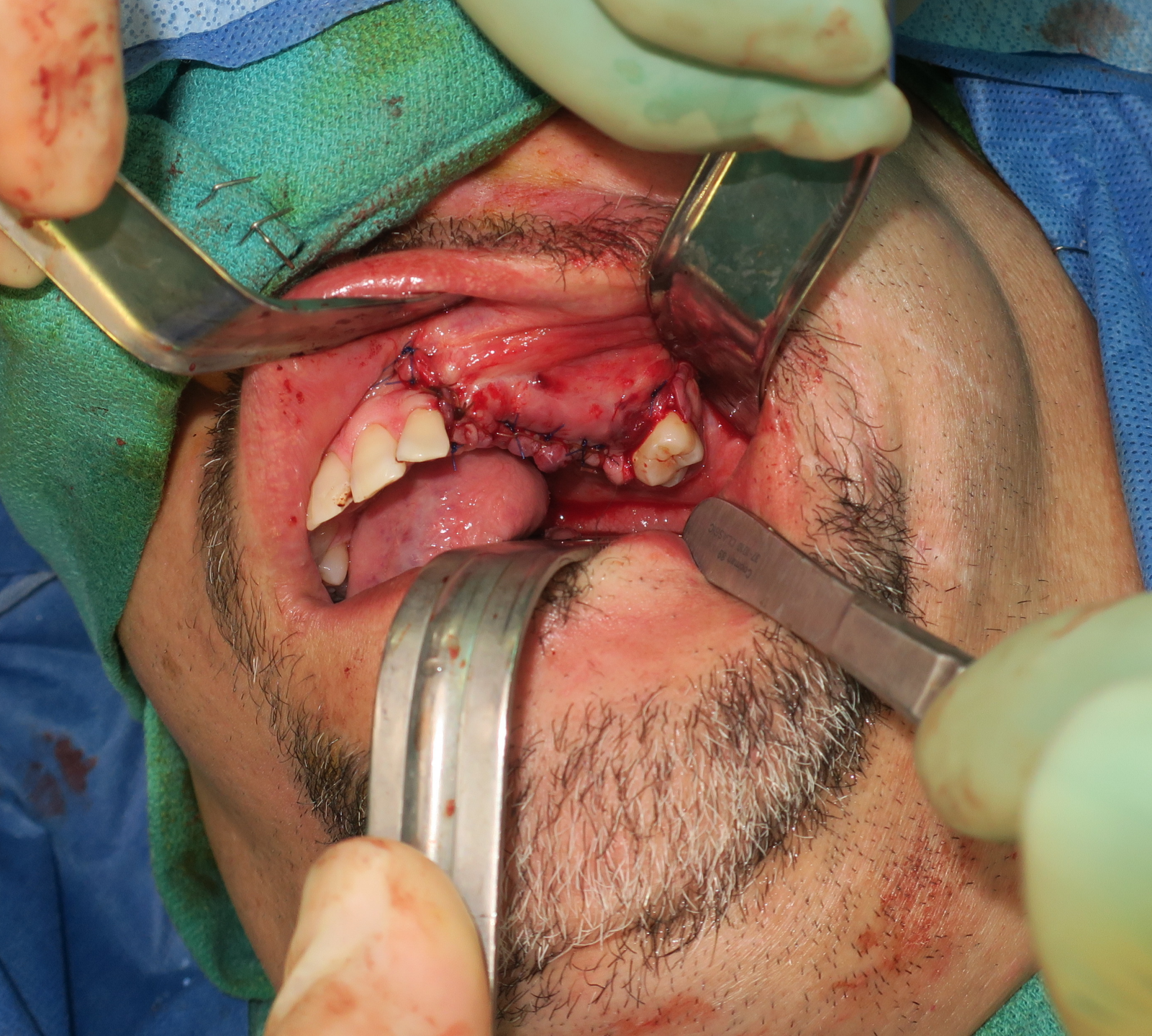
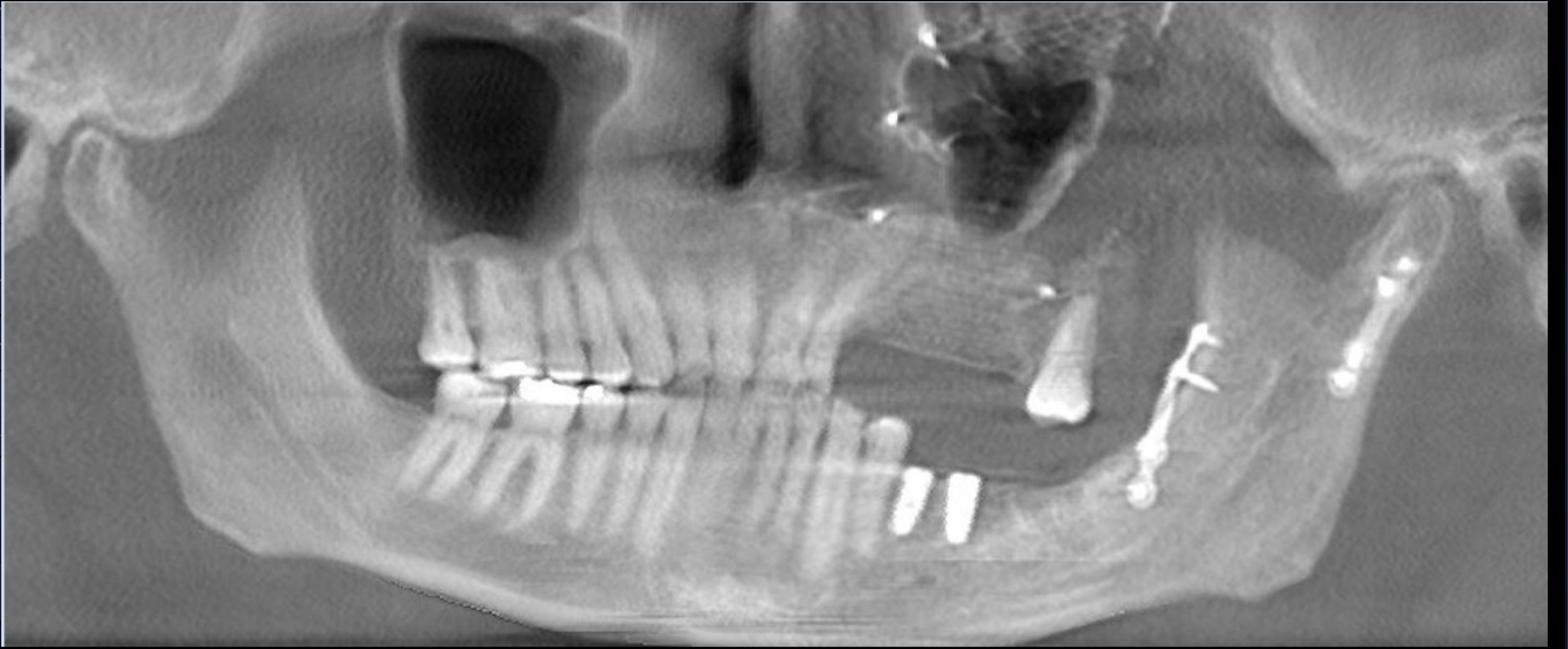


技术技术技术技术



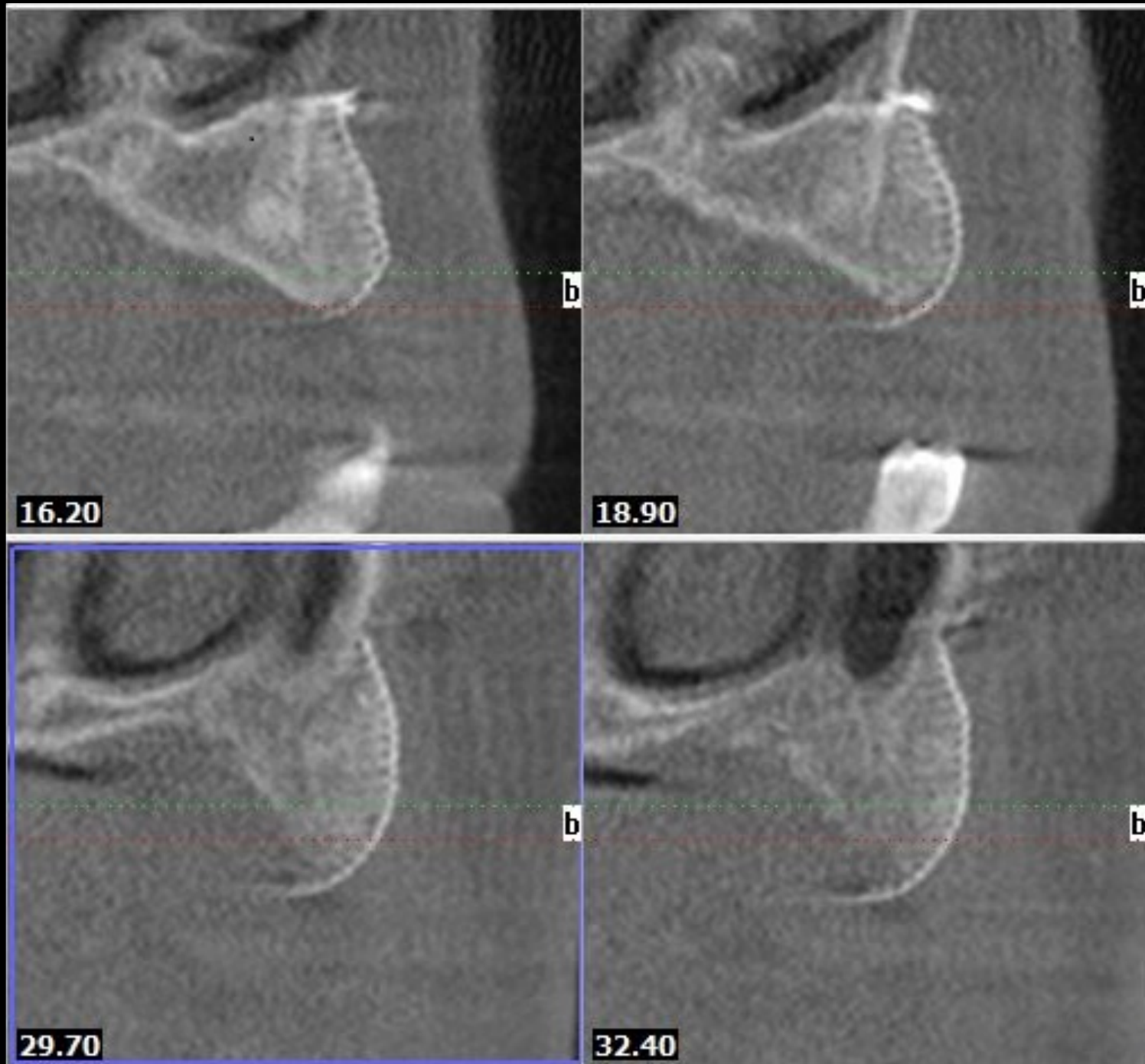

牙科材料

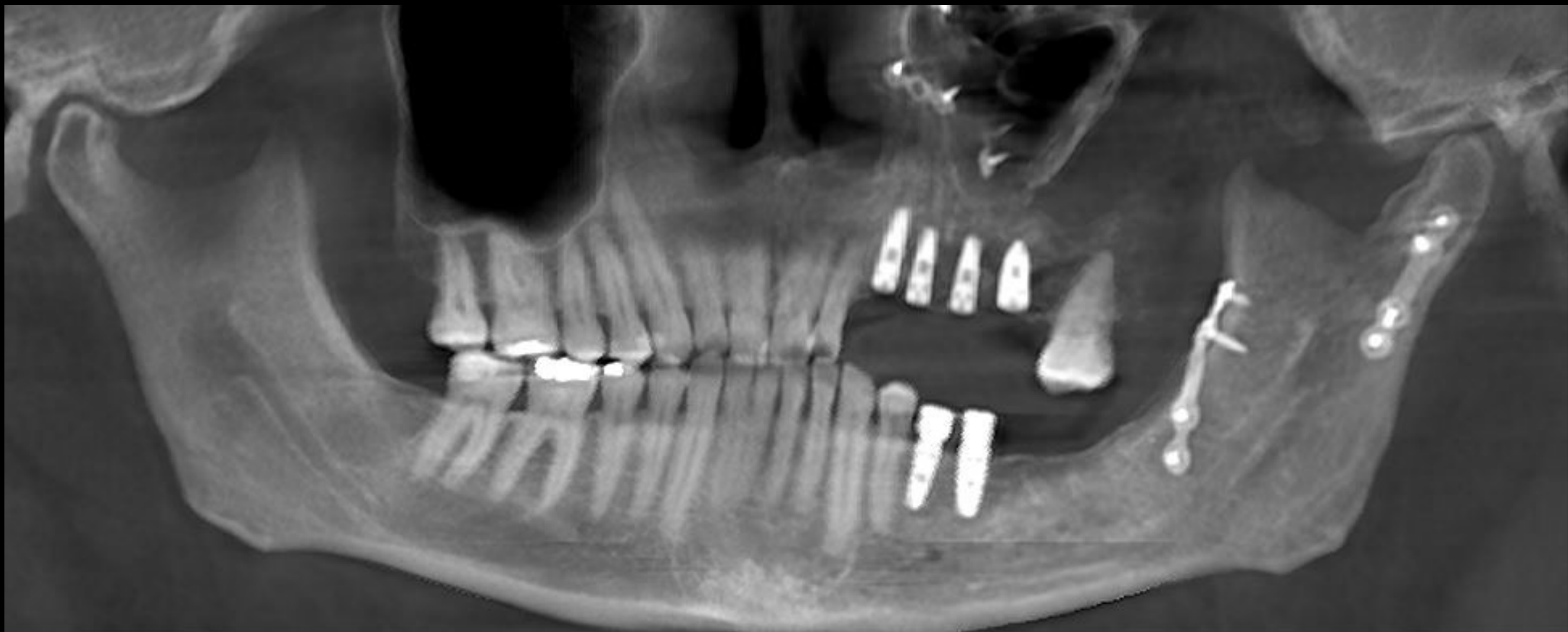





One Year Post-Grafting







Unique Nature of Case

- › General Trauma Patient
 - Follow up often limited
 - Transient Population
 - Inability to Afford Dentoalveolar Reconstruction
- › Patient has workers compensation
 - Trauma to Reconstruction



Summary

› Planning

– Fracture Identification

- › Displacement
- › Comminution

– Access

- › Determined by Displacement/Comminution
- › Fracture Junctions Requiring Fixation

– Sequencing

- › Piecing together the Puzzle

› Outcomes

- Culmination of your planning and Execution



Thank You!

MONTANA







